

"Dang! ... Stiff neck!"

- "Better call Dr Wedel"

Evaluation and Treatment of Selected Sacral Somatic Dysfunctions

Using Direct and HVLA Techniques
including
Counterstrain and Muscle Energy

AND

Counterstrain Treatment of the Pelvis
and Sacrum

F. P. Wedel, D.O.

Associate Adjunct Professor in Osteopathic Principles and Practice

A.T. Still University School of Osteopathic Medicine in Arizona, and private practice
in Family Medicine in Tucson, Arizona

Learning Objectives

- HOURS 1 AND 2

- Review the following diagnostic and treatment techniques related to sacral torsion
 - Lumbosacral spring test
 - Sacral palpation
 - Seated flexion test

- HOURS 3 AND 4

- Counterstrain treatments of various low back pathologies

Sacral Techniques Covered:

1. Prone, direct, muscle energy, for sacral rotation on both same and opposite axes
2. HVLA treatment for sacral rotation on both same and opposite axes
3. Counterstrain treatment of sacral tender points and of sacral torsion


Counterstrain

- Multifidi and Rotatores : UP5L
- Gluteii – maximus: HFO-SI, HI, P 3L- P 4L ,medius, minimus
- Piriformis

Background and Basis

The 4 Osteopathic Tenets (Principles)

1. The body is a unit; the person is a unit of body, mind, and spirit.
2. Structure and function are reciprocally inter-related.
3. The body is capable of self-regulation, self-healing, and health maintenance.
4. Rational treatment is based upon an understanding of these basic principles.



Somatic Dysfunction - Defined

- “Impaired or altered function of related components of the somatic (body framework) system:
 - Skeletal, arthrodiar, and myofascial structures,
 - And...
 - Related vascular, lymphatic, and neural elements”

Treatment Options for Somatic Dysfunctions

- All somatic dysfunctions have a restrictive barrier which are considered “pathologic”
- This restriction inhibits movement in one direction which causes asymmetry within the joint:
- The goal of osteopathic treatment is to eliminate the restrictive barrier thus restoring symmetry.....

Somatic Dysfunction: CHARACTERISTICS

“The acronym TART is used to remember the abnormal changes that accompany somatic dysfunction. (Tenderness by itself is not always an indication of somatic dysfunction):

- **Tissue texture changes**
- **Asymmetry**
- **Restricted range of motion**
- **Tenderness**

Kimberly Manual, chapter 3

Treatment Methodologies

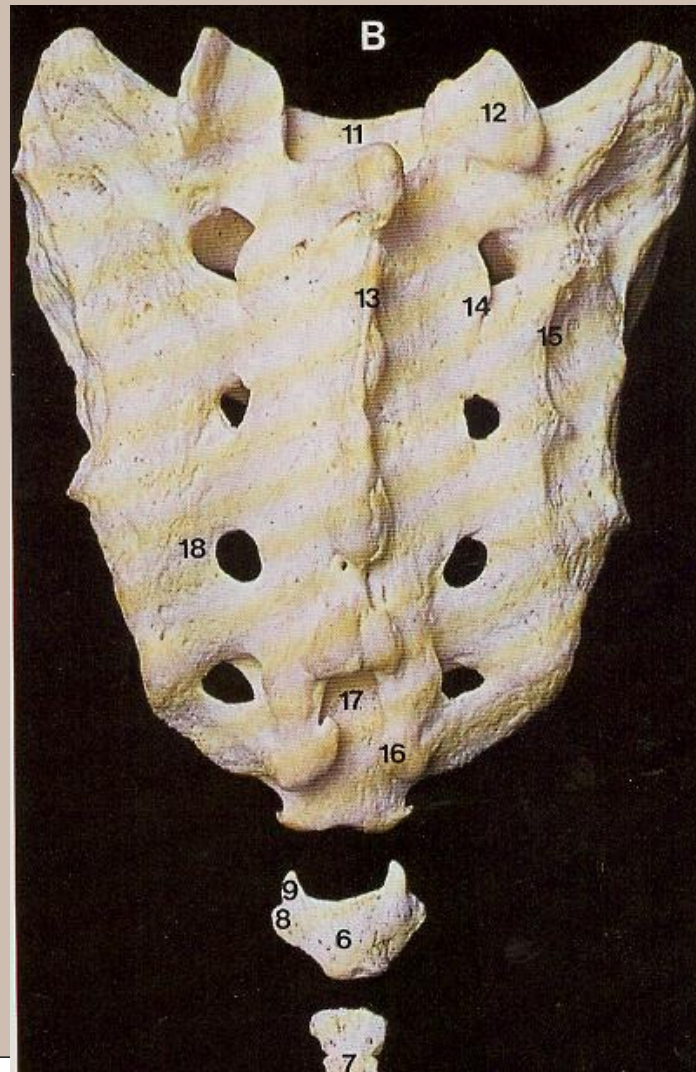
- Indirect – movement away from the barrier and more functional than structural
 - Cranial-sacral
 - Counterstrain
 - Balanced ligamentous tension (BLT)
 - Facilitated Positional Release
- Direct – engagement of the restrictive barrier and movement through it and to it by using the body part as a lever
 - Muscle Energy and MFR
 - HVLA
 - Chapman's and Lymphatics

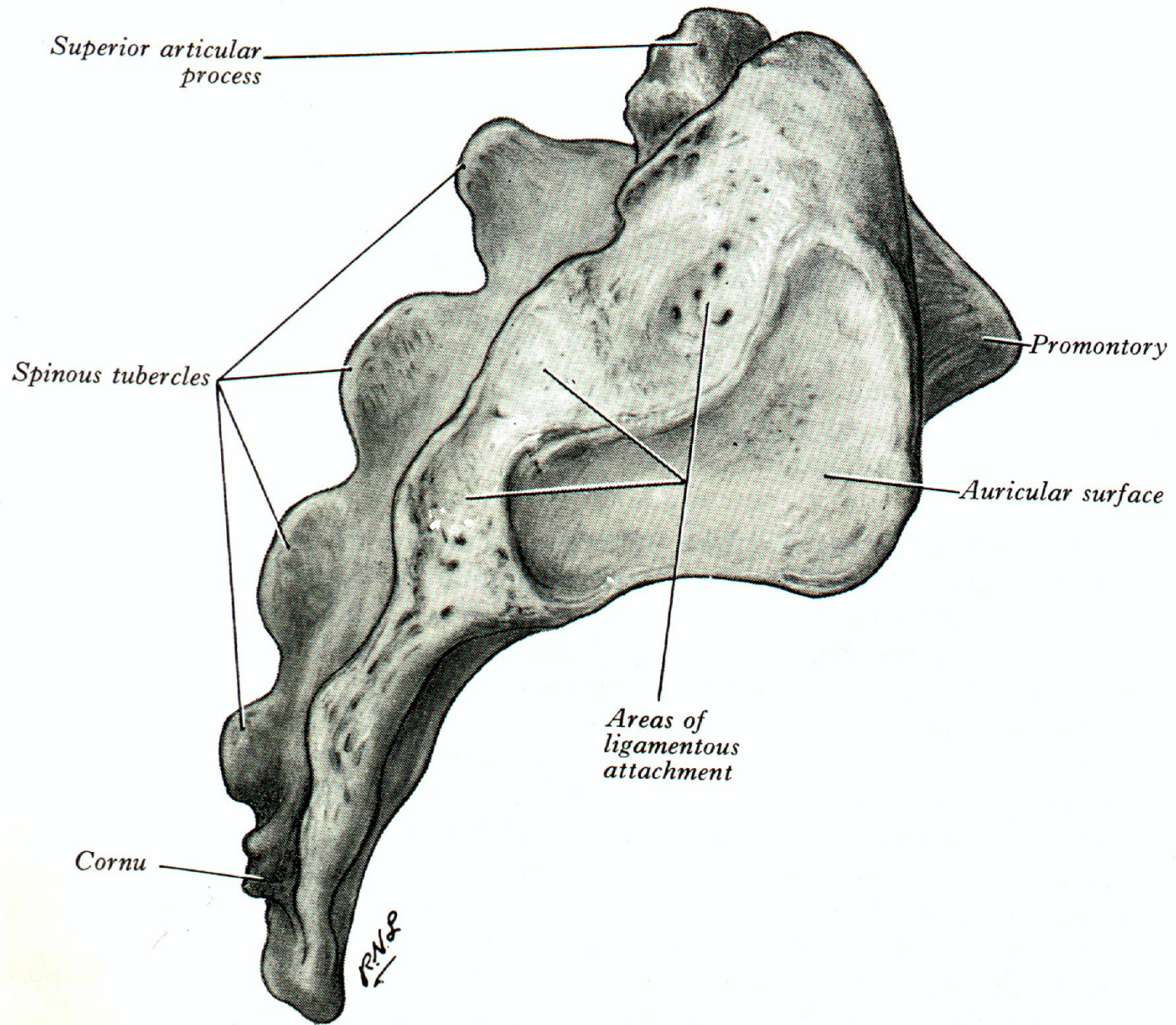
SACRAL
STRUCTURE, LIGAMENTS AND
MUSCLES

THE SACRUM

Means “sacred”

because of its density it is the last bone to decay and because it protects the reproductive system



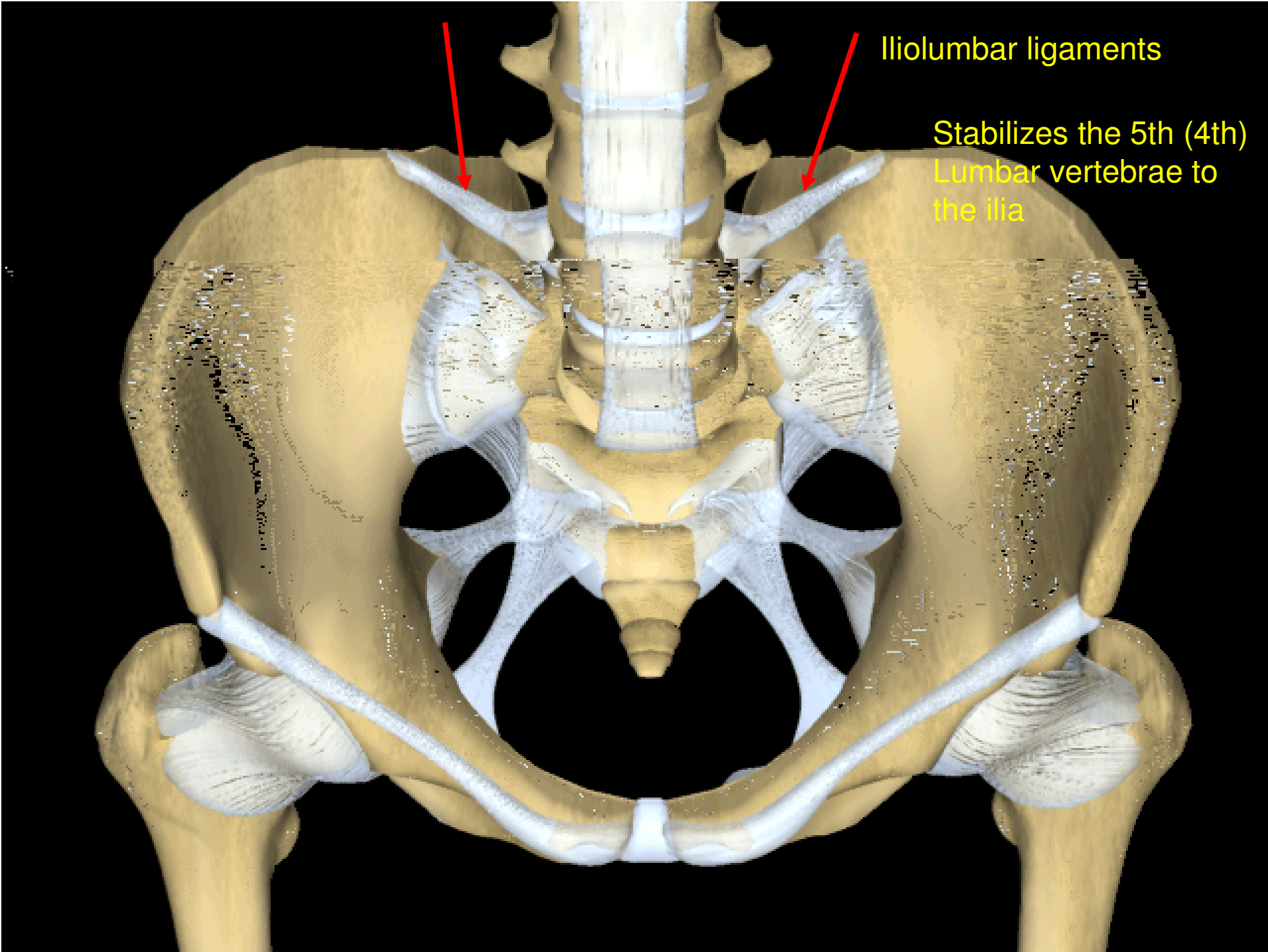


Forces on the sacrum

- Angle of the sacroiliac joint “wedges” the sacrum in an anterior direction
 - Prevents posterior movement
- Dorsal (posterior) sacroiliac ligaments much stronger than anterior sacroiliac ligaments
- Purpose: counteract significant pelvic forces pushing apex posteriorly.

Major Pelvic Ligaments

- Iliolumbar
 - from ilia to 5th lumbar vertebrae
- Sacrospinous
 - Sacrum to spine of the ischium
- Sacrotuberous
 - Sacrum to ischial tuberosity
- Sacroiliac Ligament
 - Covers much of the sacroiliac joint, ant & post

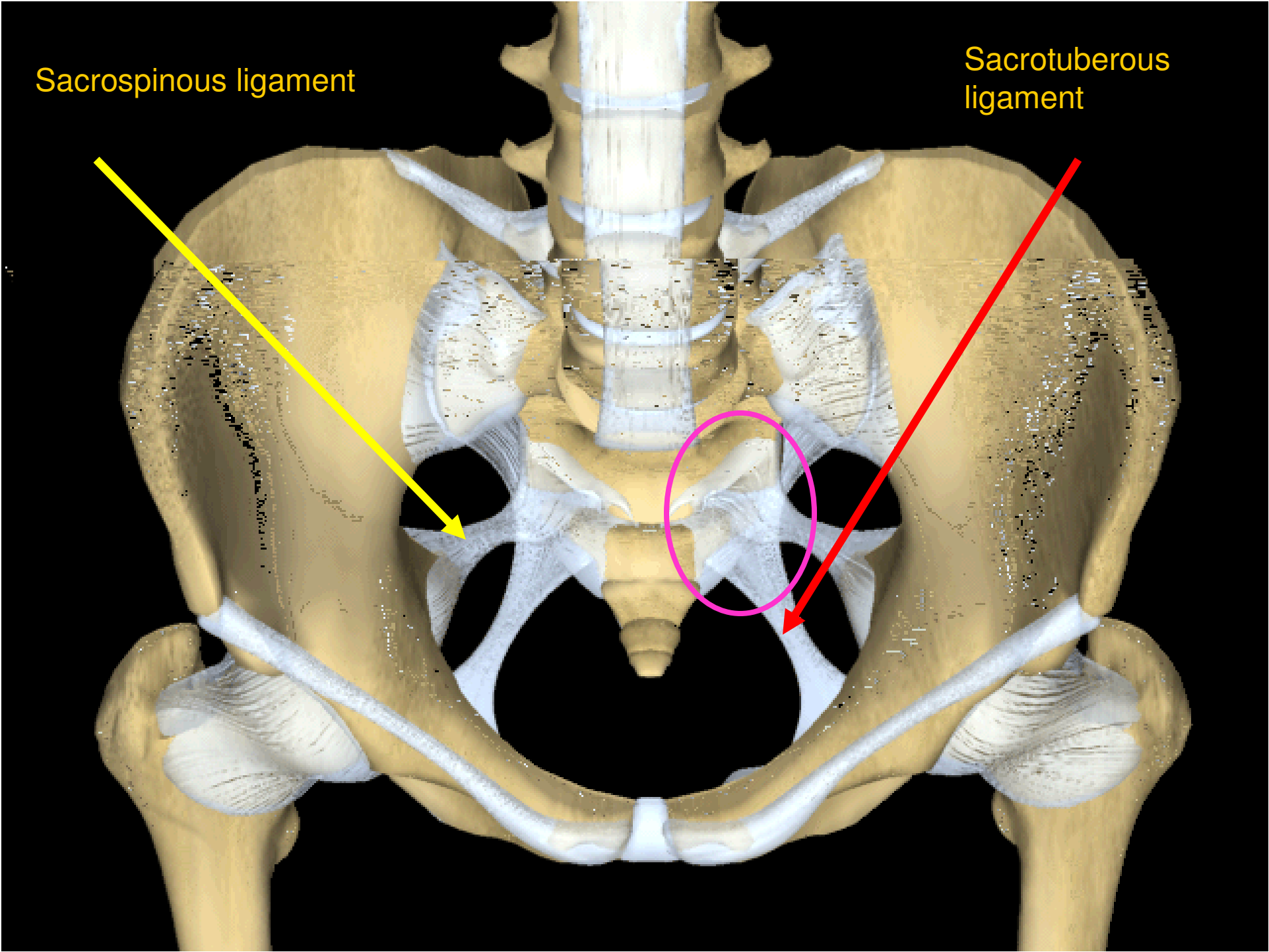

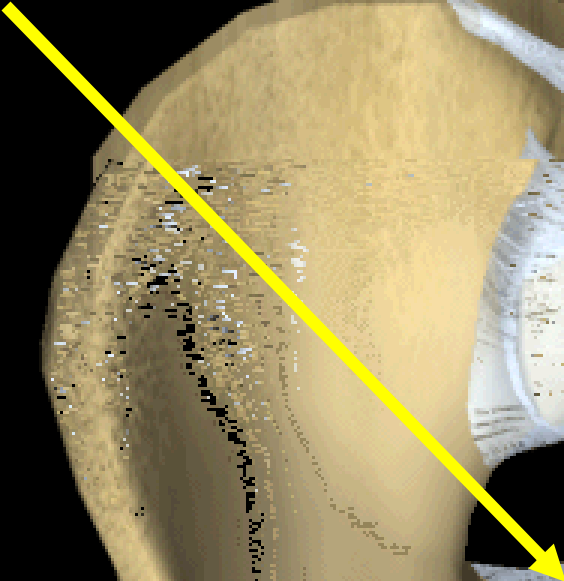


Iliolumbar ligaments

Stabilizes the 5th (4th)
Lumbar vertebrae to
the ilia

Sacrospinous ligament

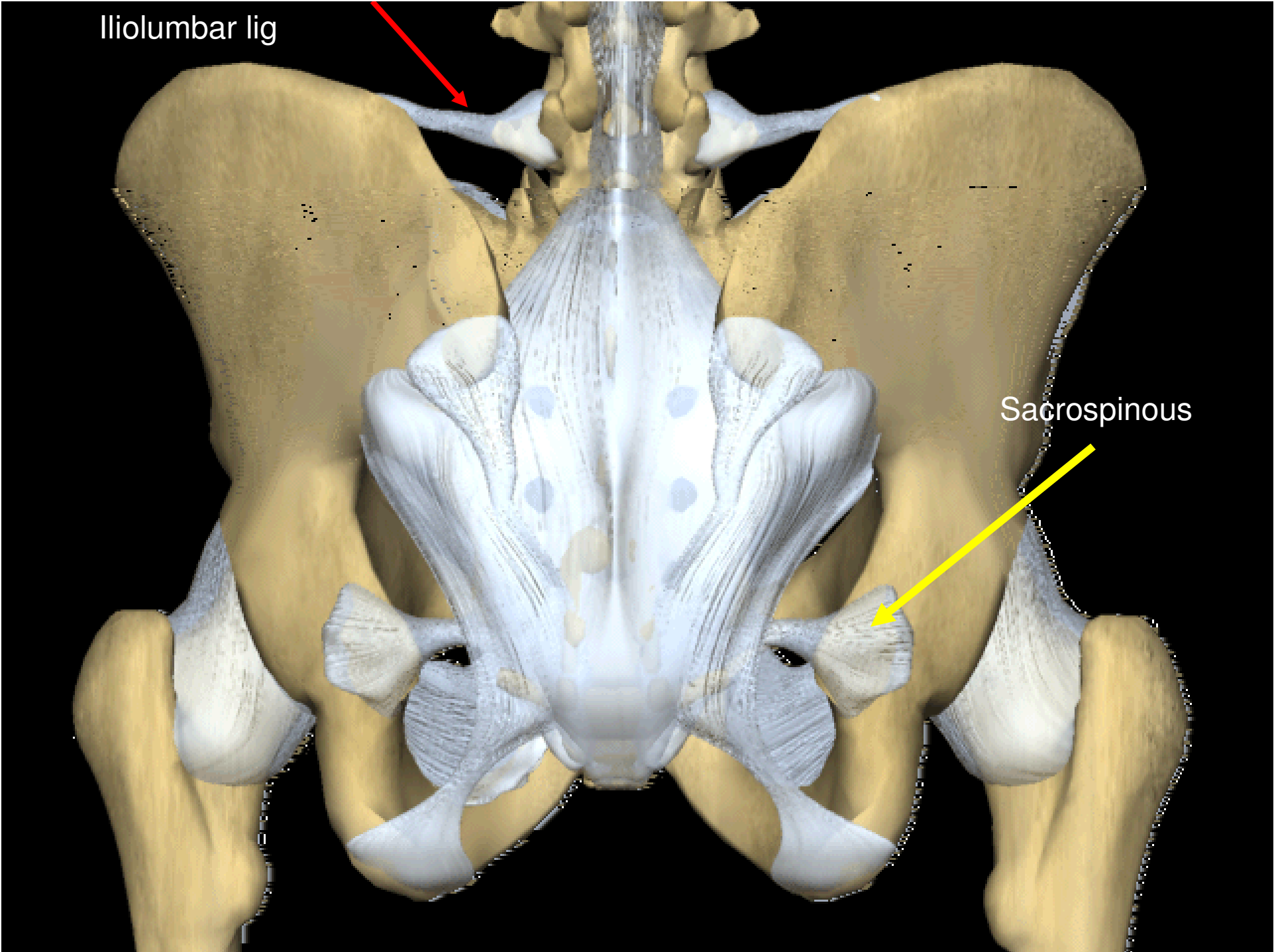
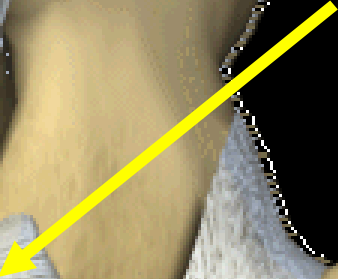
Sacrotuberous ligament



Iliolumbar lig



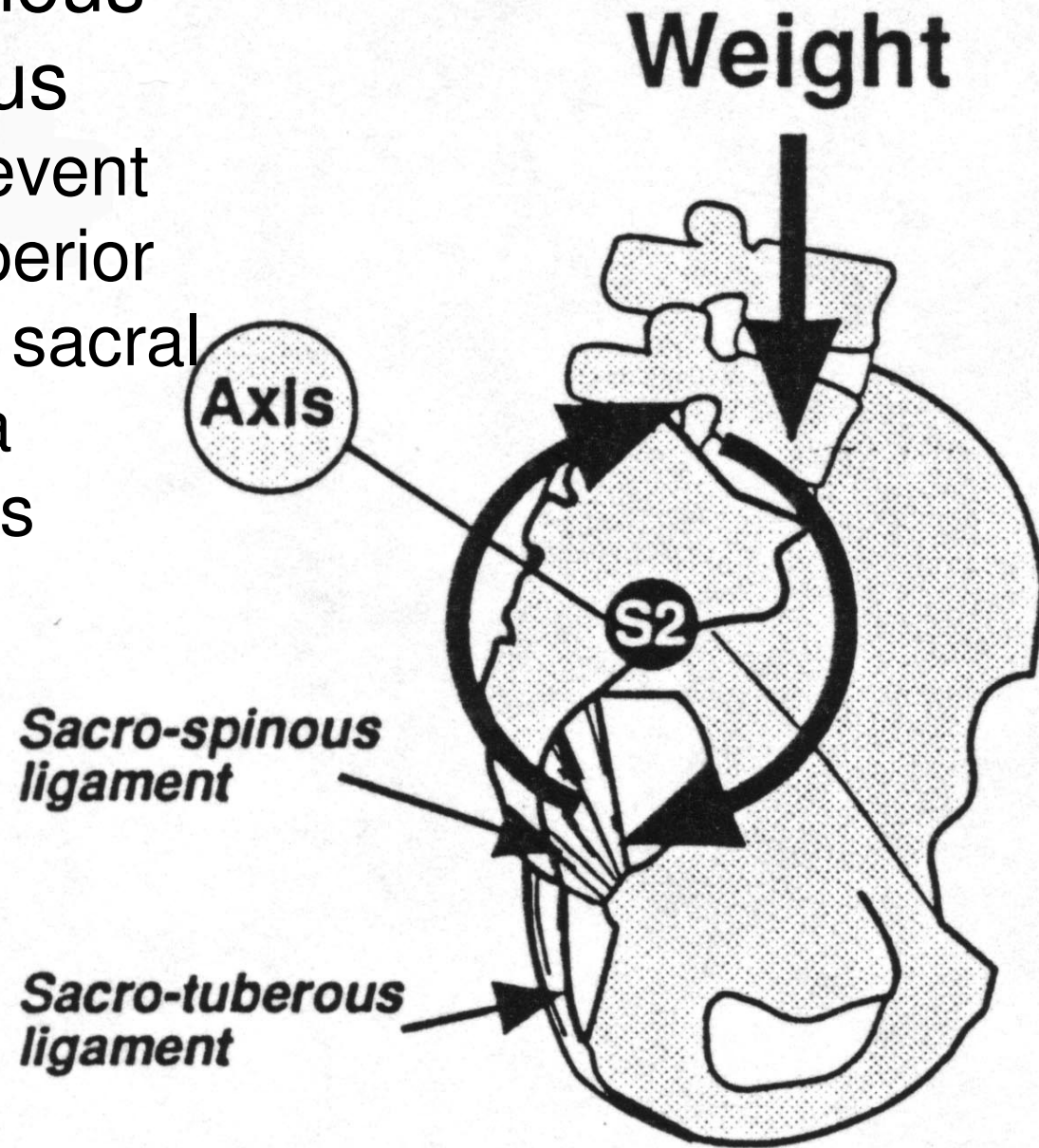
Sacrospinous



Sacrospinous Ligament

- Runs from lower sacral tubercles to ischial tuberosity
- Gluteus maximus attachment
- Tendon of the biceps femoris attachment
- Connects with fascia of the pelvis
 - from sacrum to ischial tuberosity
 - stabilizes anterior motion

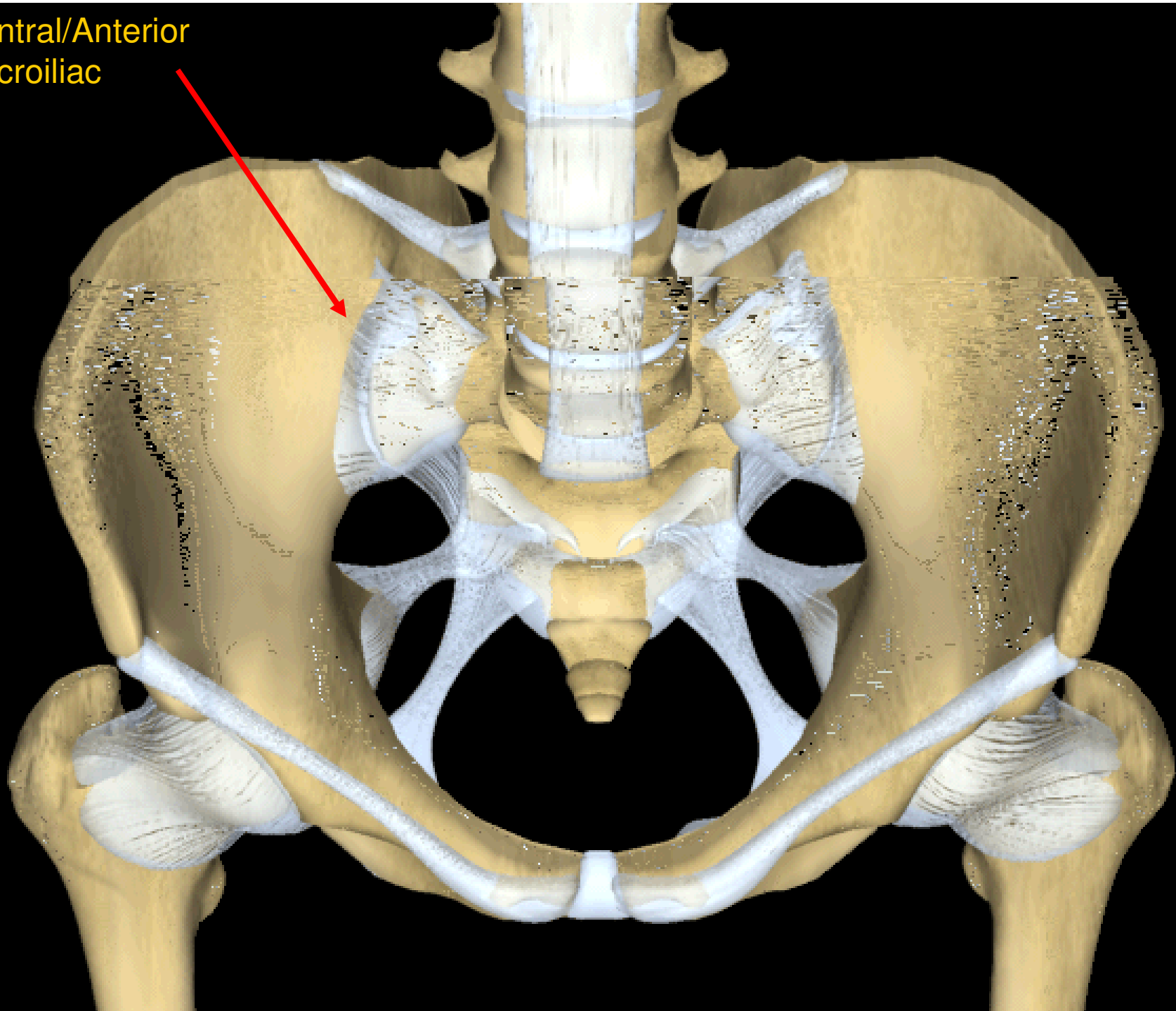
Both Sacrospinous & Sacrotuberous stabilize to prevent posterior - superior *rotation* of the sacral apex around a transverse axis



Sacroiliac Ligament

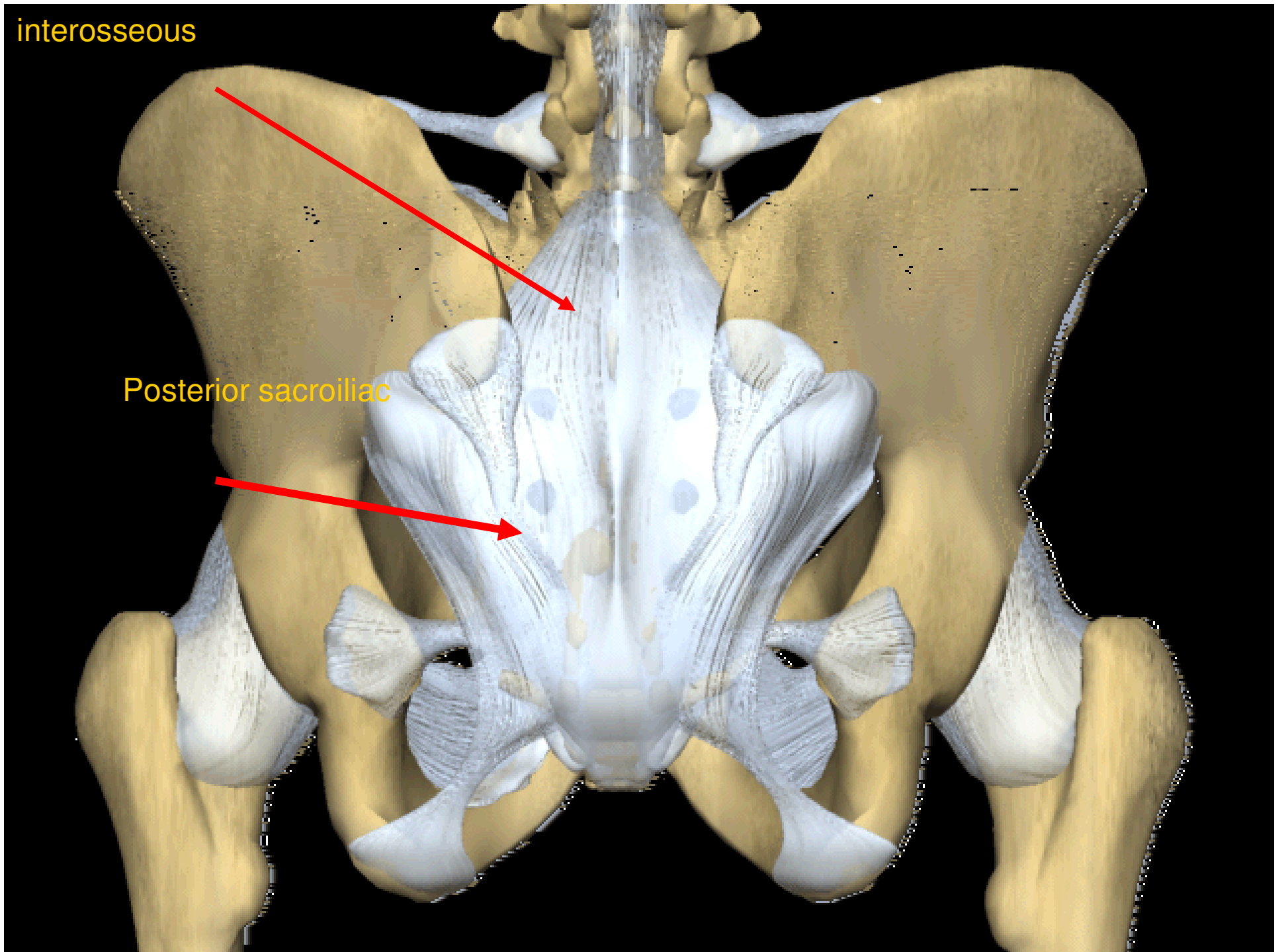
- Sacroiliac
 - **actually three ligaments**
 - Anterior or ventral sacroiliac
 - from 3rd sacral segment to lateral preauricular sulcus
 - interosseous sacroiliac
 - massive bond between the upper parts of the joint
 - dorsal sacroiliac
 - Partly covers the interosseous, from lateral sacral crest to PSIS and internal iliac crest.

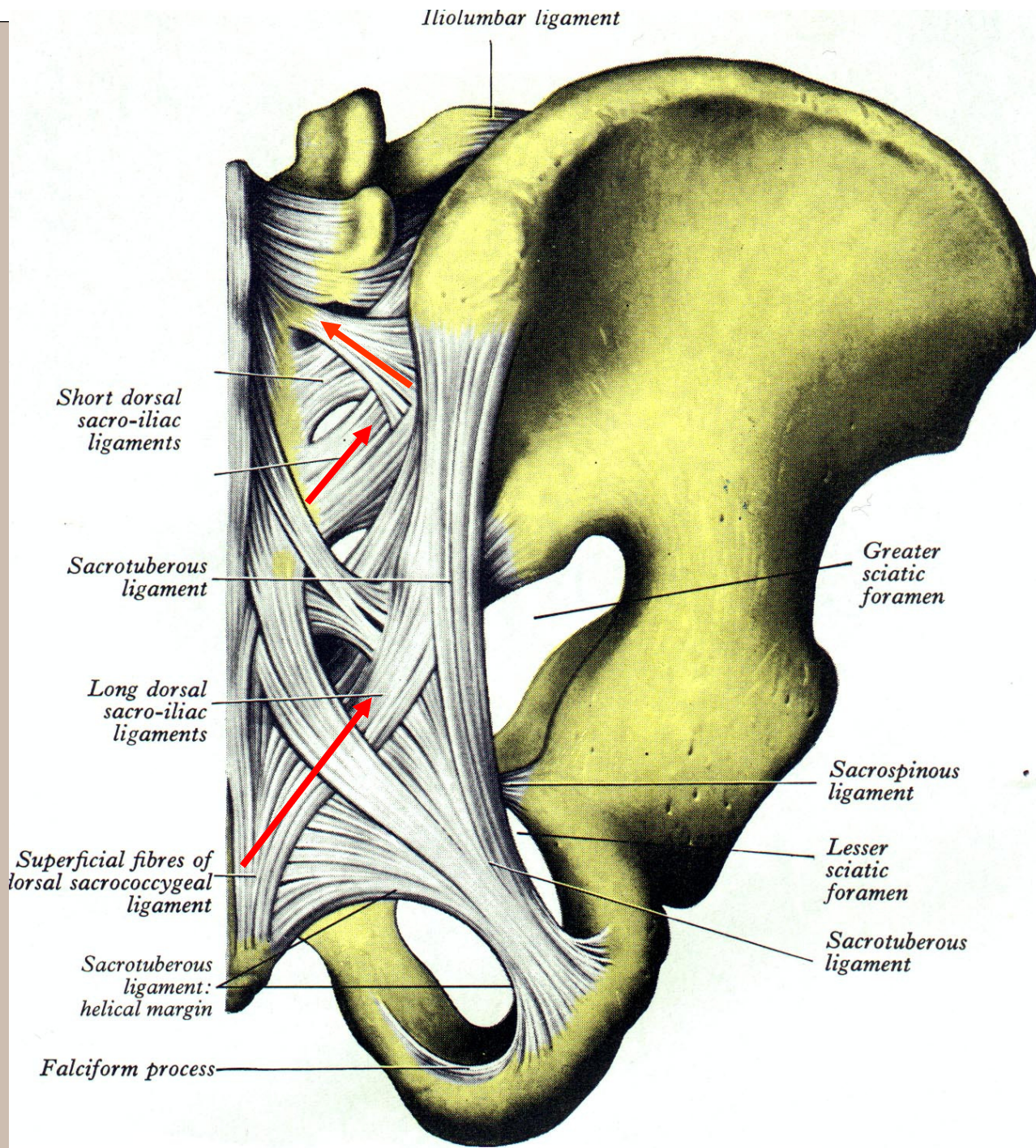
Ventral/Anterior
Sacroiliac



interosseous

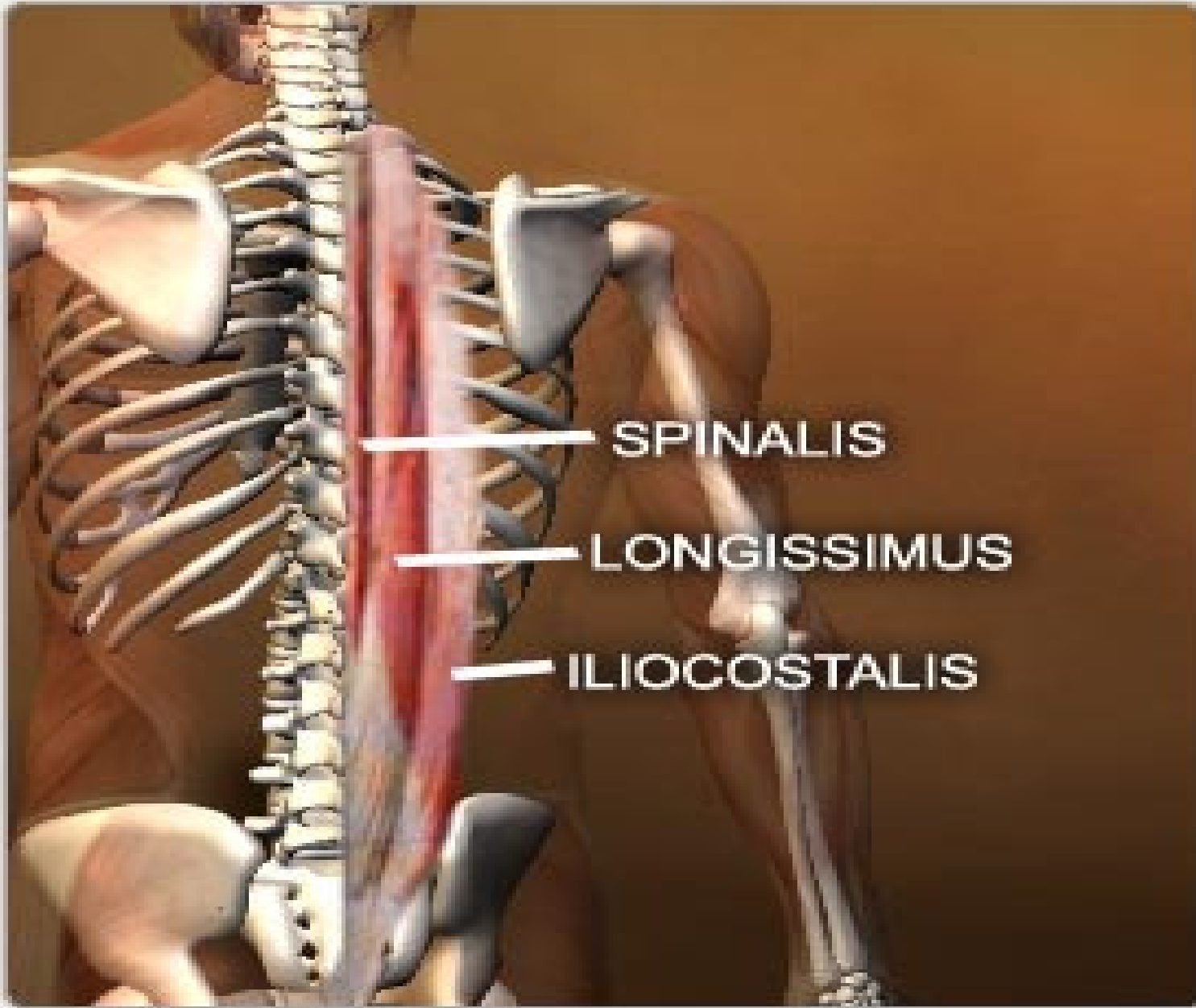
Posterior sacroiliac





Pelvic muscle attachments from above.

- Attach to Sacrum
 - Erector Spinae
 - Iliocostalis
 - Longissimus
 - Spinalis
 - Multifidus
- Attach to Innominates
 - Obliques (internal, external, transverse)
 - Quadratus Lumborum

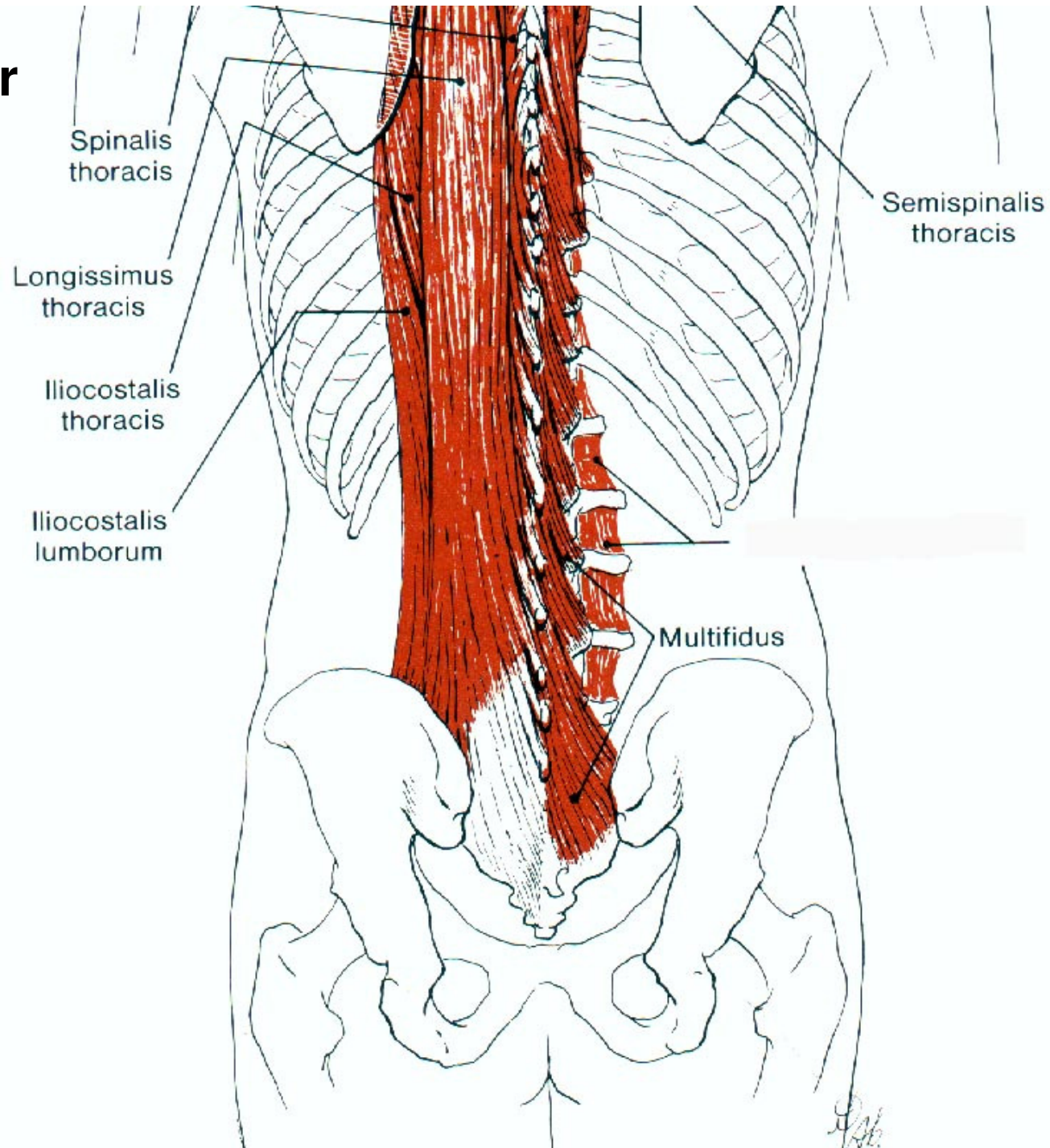


SPINALIS

LONGISSIMUS

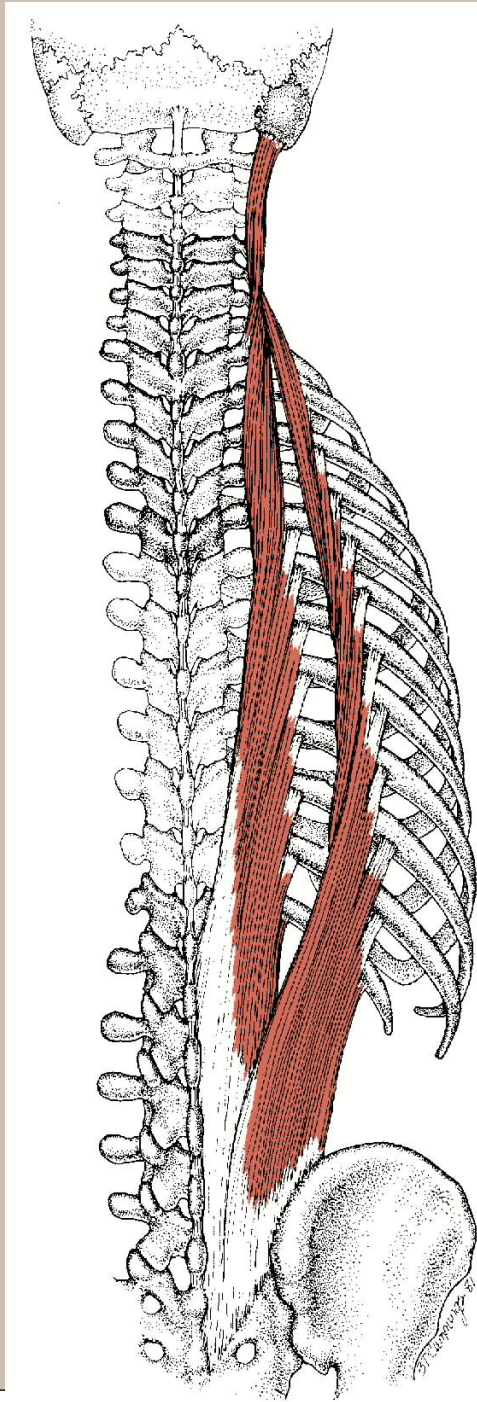
ILIOCOSTALIS

Posterior Muscles



Erector Spinae

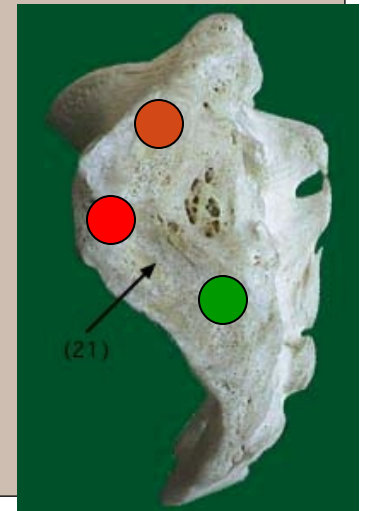
(sacrospinalis
and iliocostalis)



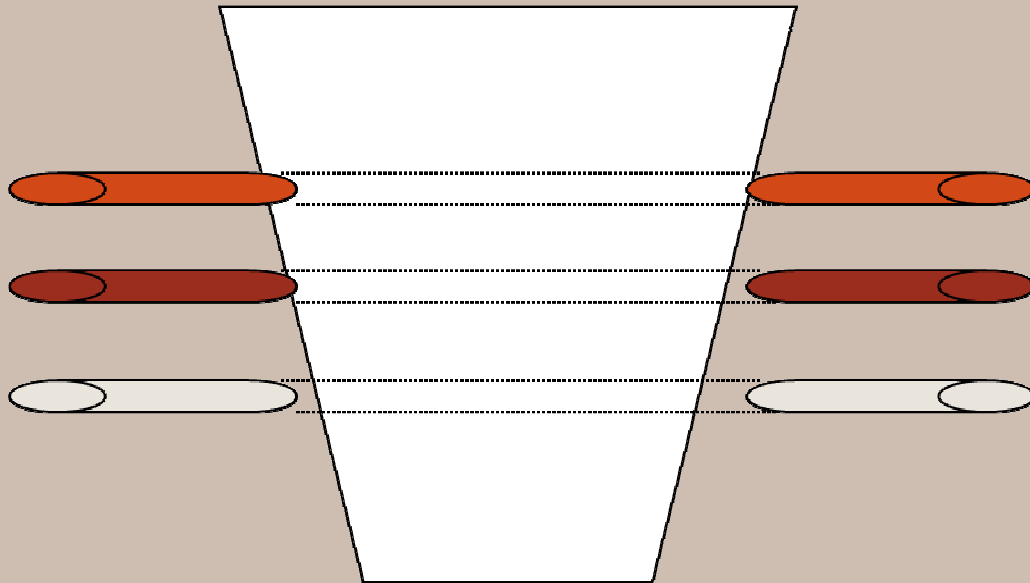
SACRAL ANATOMICAL AXES

Transverse axis

- **Superior**: the cranial & primary respiratory mechanism creates motion around this axis
- **Middle**: sacral base anterior and posterior (FB/BB) occur around this axis
- **Inferior**: the innominates rotate around this axis



SACRAL MOTION



Respiratory motion: inhalation
sacral base moves posteriorly
(counter-nutates)

Respiratory exhalation: sacral base
moves anteriorly (nutates)

Inherent (craniosacral) motion:

***Craniosacral flexion-base
rotates posteriorly (counter-
nutates)

Craniosacral extension-base
rotates anteriorly (nutates)

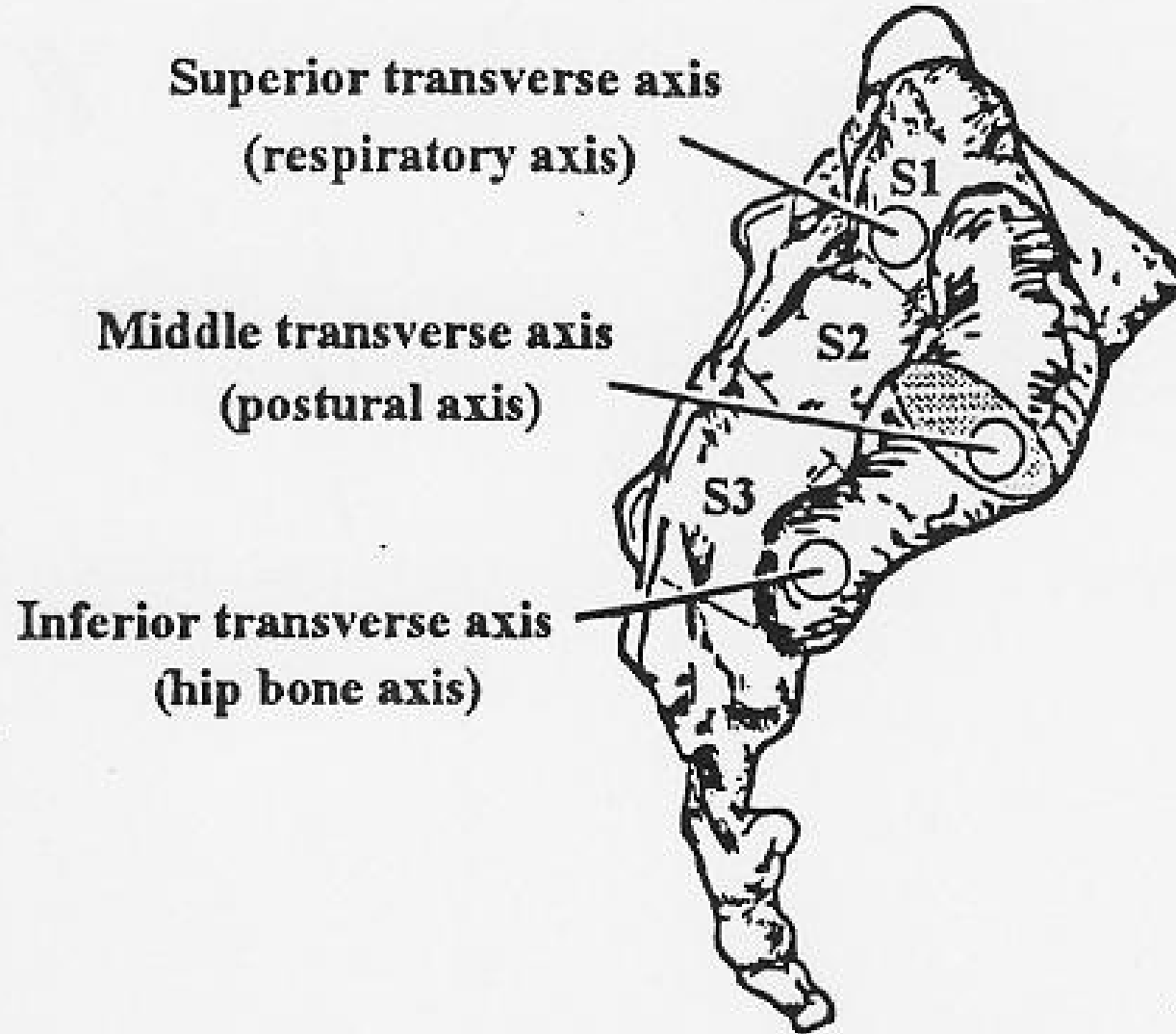
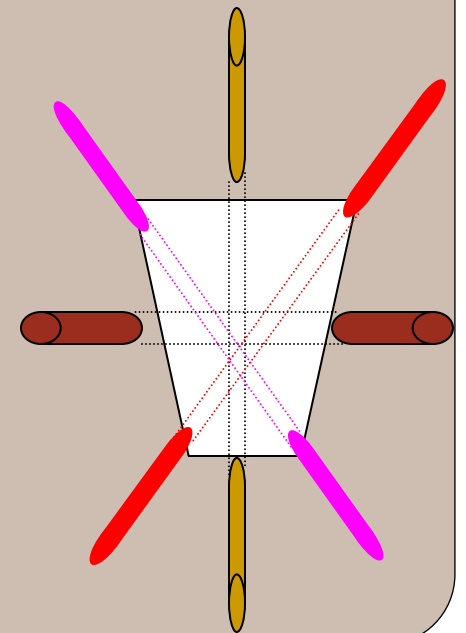


Figure 19. Sacral transverse axes

SACRAL PHYSIOLOGIC AXES


- Oblique: both **left** and **right** oblique axes are named for the superior pole
- Sagittal: includes both mid-sagittal and an infinite number of parasagittal axes
- Horizontal: functional axis of sacral flexion/extension occur around this axis (analogous to the middle transverse axis above)



(footnote on functional anatomy)

Why are the Oblique Axes so significant?

They are the Axes of Walking.



The walking cycle as it applies to our discussion

1. From a standing (**neutral**) position, when you take a step forward, your weight is shifted onto one lower extremity.
2. This induces spinal column SB to the weight bearing side, and pins the upper pole of the sacrum on the side of the SB.
3. As the free lower extremity swings forward, it carries the free pole of the sacrum anterior, creating rotation of the sacrum about the Oblique Axis, towards the weight bearing extremity.

Ex.: R_L on LOA



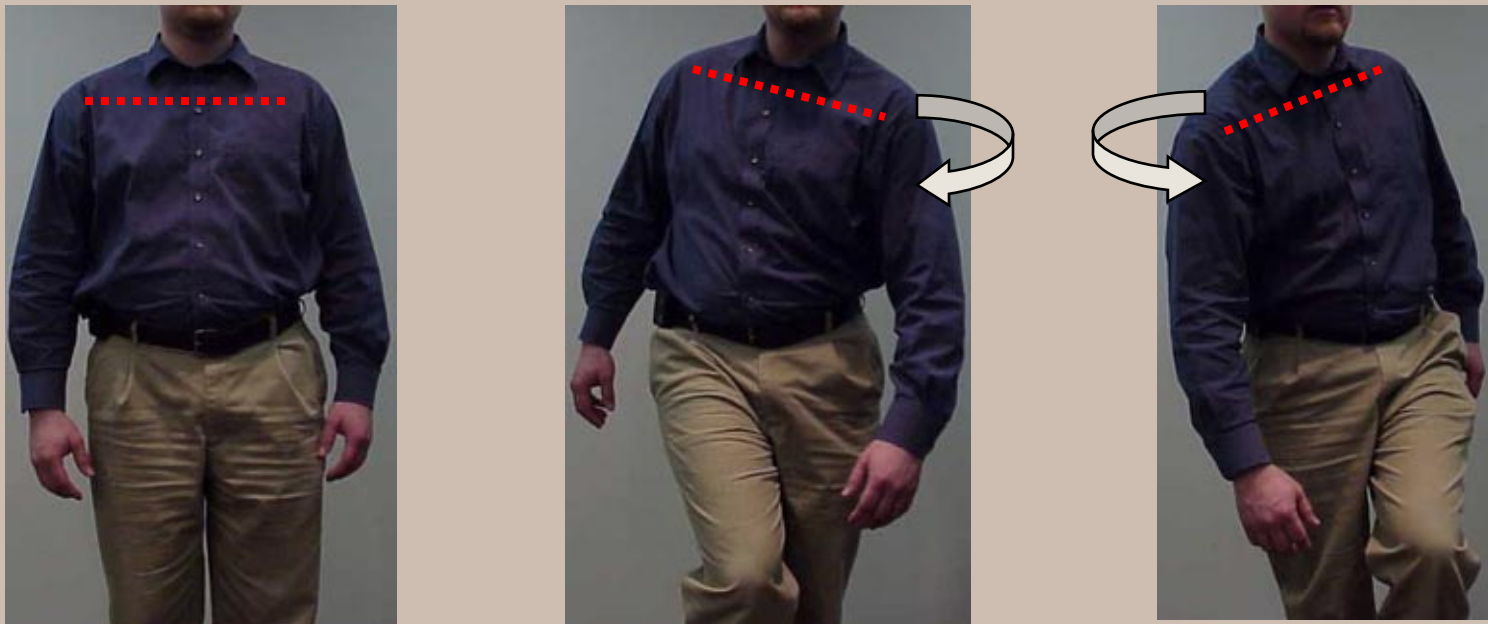R_R on ROA



Bottom Line: [You form Oblique Axes with every step you take!](#)

The other aspect of the walking cycle is the movement of the torso.

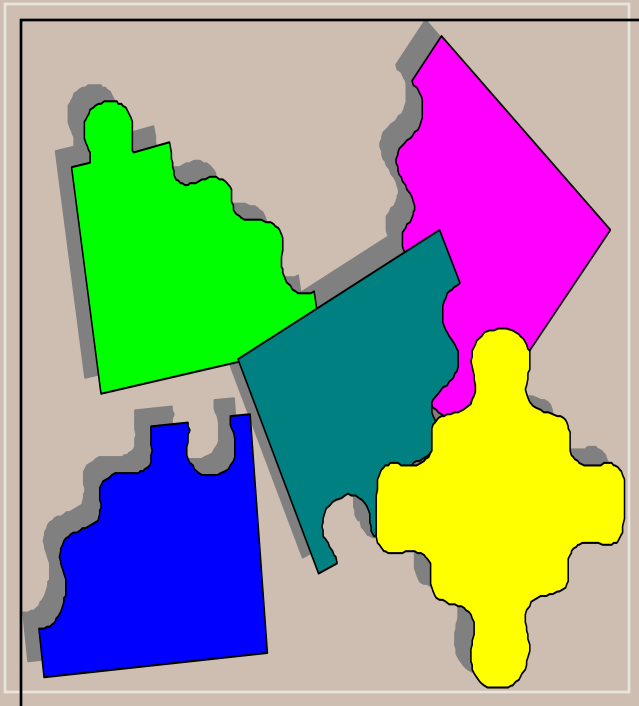
1. From a standing (**neutral**) position, as you step forward, note how your body compensates. What does your torso do?
2. Answer: Rotates towards the moving lower extremity (ie.: away from the weight bearing lower extremity).



Bottom Line: Your spine (most notably Lumbar spine) rotates in the opposite direction of the sacrum in a neutral moving situation.

TESTS

To make a Sacral Diagnosis you will need to know the following:

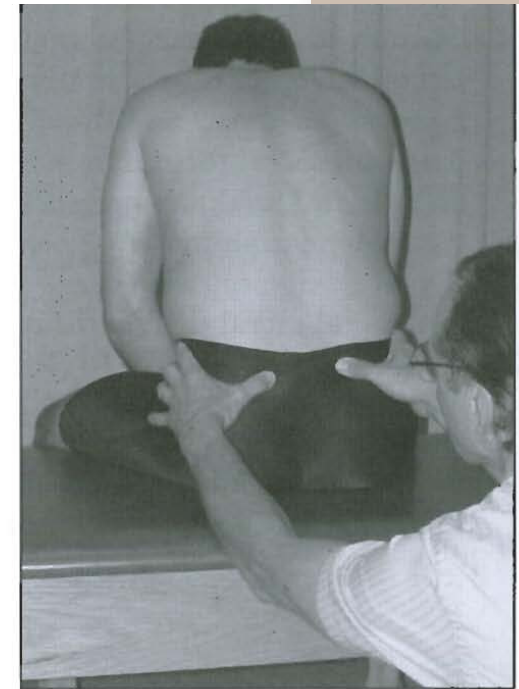


- Static (Pure) Landmarks
 - Sacral base - Ant/ Post
 - ILA -Ant/Post
 - ASIS & PSIS -Sup./Inf.
 - Pubes -Sup./Inf & Ant./Post
- Mixed Landmarks
 - Sacral Sulcus - Deep/ Shallow
 - STL - Tight/ Loose/ Equal
- Motion Testing
 - Spring test
 - L5
 - Sacrum

Seated Flexion Test

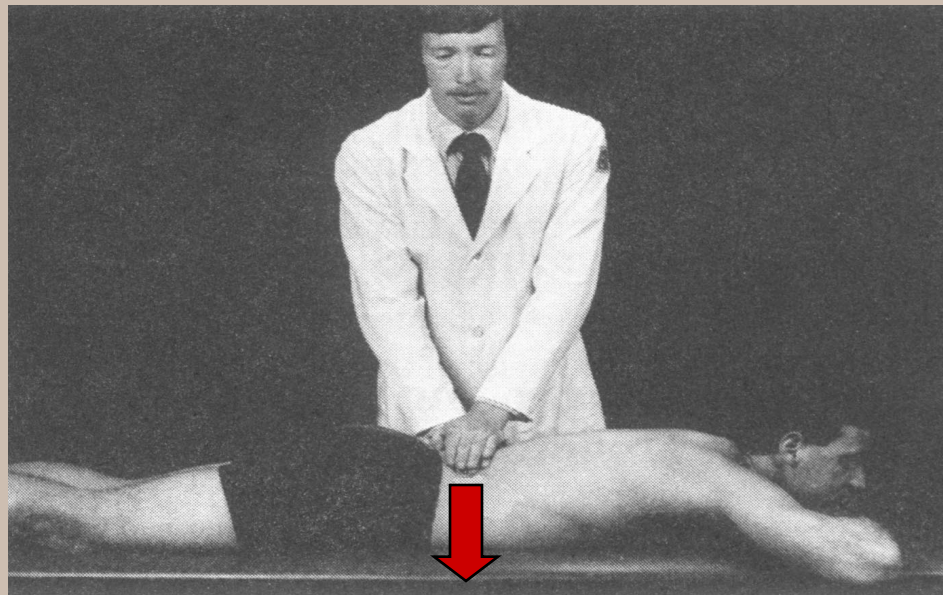
1. Place your thumbs on the undersurface of the posterior superior iliac spines (PSIS) of the seated patient, taking care to keep both thumbs horizontal;
2. Ask the patient to bend forward with feet on the floor and allow your thumbs to follow PSIS movement, taking care to maintain both thumbs underneath the PSIS;
3. The side on which the PSIS stops moving superiorly the last is the side of sacrum restriction at the sacroiliac joint;
4. False positives: pelvis somatic dysfunction on same side.

•Record Positive Right, Positive Left, or Negative Test



Spring Test

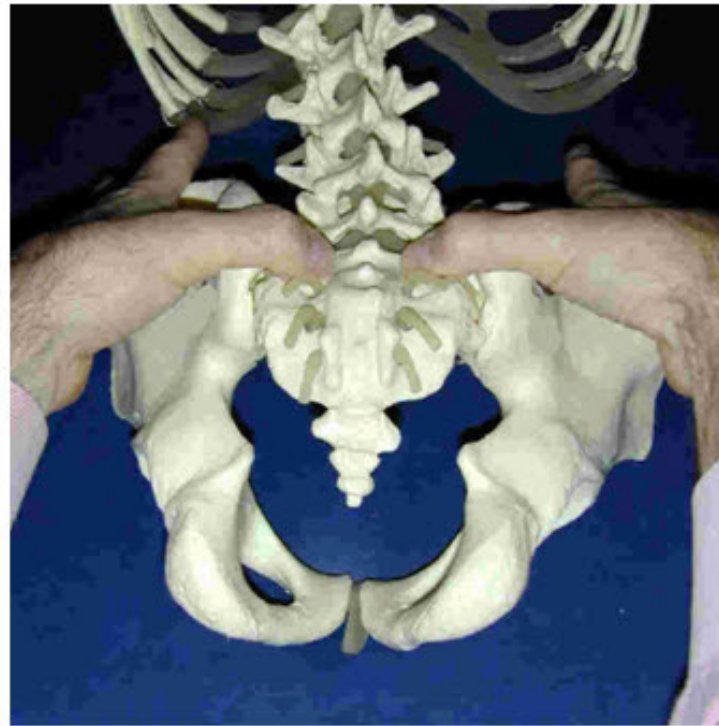1. Find sacral base
2. Place heel of hand over Lumbosacral junction
3. Spring in an Anterior motion
4. Results:
 - a. Positive test = If there is NO springing allowed = Non-neutral condition
(AKA Backward torsion)
 - b. Negative test = If there is springing allowed = Neutral condition.



Prone Landmarks

Sacral Base

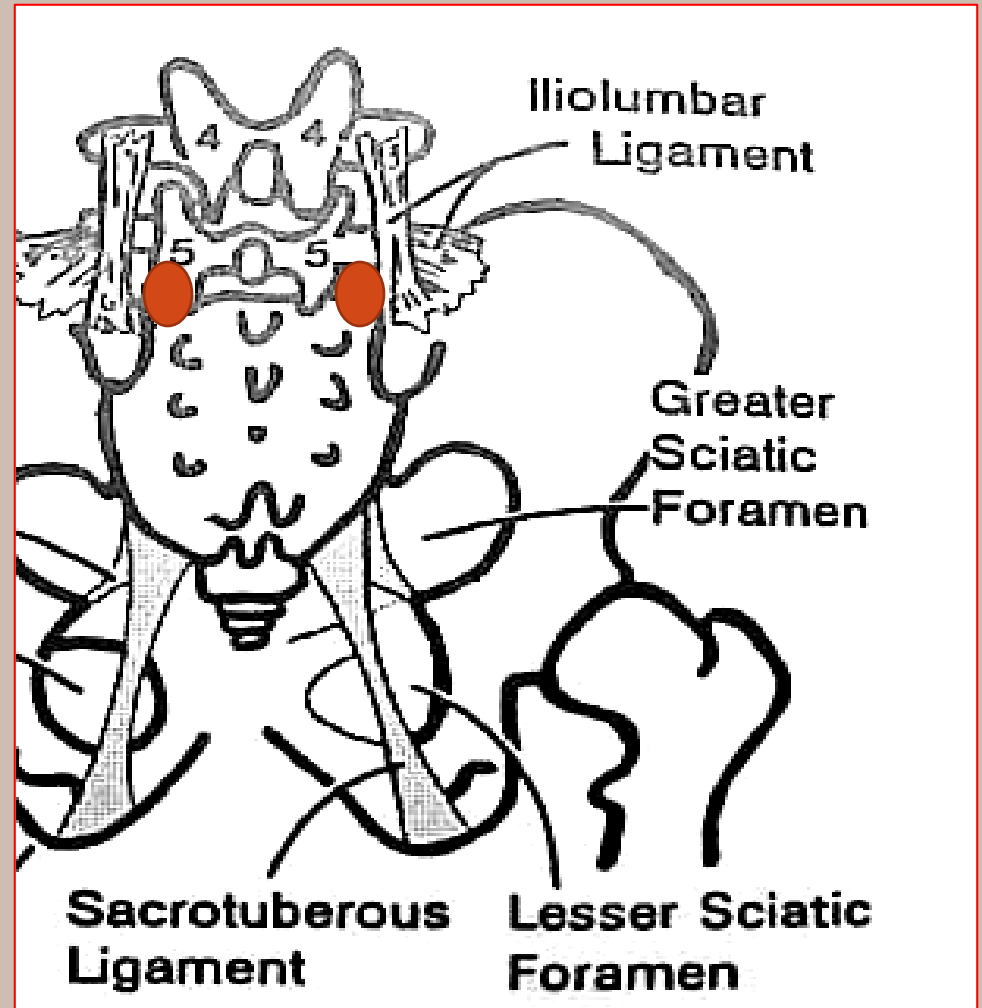
- Judge whether the tip of the thumb is more anterior on one side than the tip of the thumb on the other side.
- Can also bring index fingers over onto sacral base and take measurement on the lateralized side.
- Record which base is anterior.



Sacral base palpation

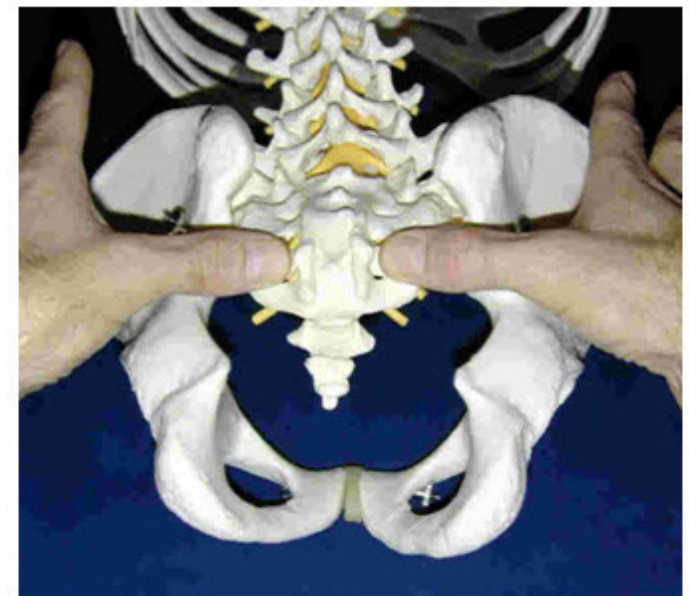
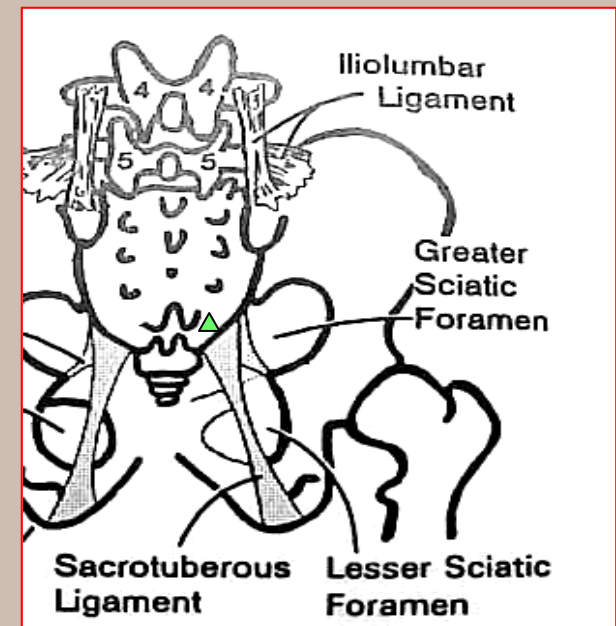
Sacral Sulcus Depth

- Palpable groove just medial to PSIS.
- Space between sacral spines and lateral sacral crest.
- Place thumbs in inferior border of PSIS.
- Move ½-1” up and medial to PSIS.
- Push thumb tips on sacral base.
- Pads of thumbs are on ilium and tips on sacral base.
 - Measure the depth of each sacral sulcus relative to opposite sulcus?
 - Record even, deep, or shallow, comparing one side to the other.
 - Both sides may be shallow or deep as well.



Inferior Lateral Angle

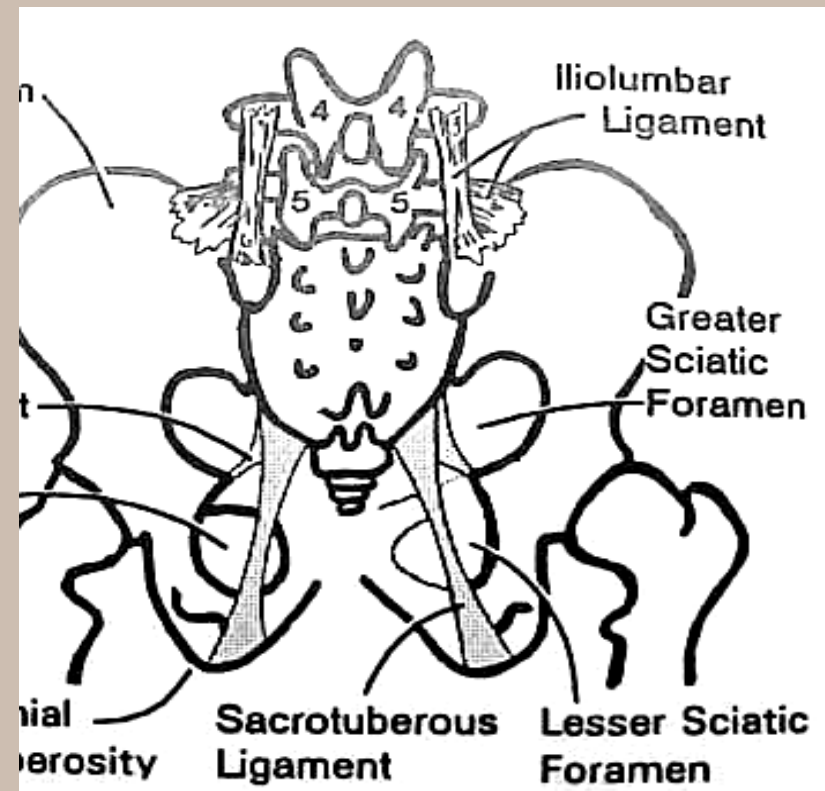
- 1. Place flat of hand over sacrum near its caudal end and identify the coccyx.
- 2. Thumbs approximately 1" apart. Place thumbs in gluteal area about 1" caudal and on each side of coccyx.
- 3. Push thumbs cephalad until pads rest on inferior margin of ILA. Take a reading on the lateralized side: Inferior or superior? Possibly even?
- 4. Move thumbs approximately 1" cephalad from the inferior margin of the ILAs and place the pads of the thumbs over the posterior surface of the ILAs near the apex of the sacrum.
- 5. Use moderate equal pressure & judge if one side is more anterior or posterior than the other one or are they equal? Record on the lateralized side.



ILA palpation

- 1. Place thumbs on the inferior margin of ILA.
- 2. Move thumbs inferiorly and laterally from the ILA bilaterally, palpating for the sacrotuberous ligament.
- 3. Ligament will be found between the ILA and the ischial tuberosity on each side.
- 4. Press thumbs anteriorly, superiorly, and 45-50 degrees laterally to check the tension on the sacrotuberous ligaments.
- 5. Are they equal in tension or is one tighter or looser than the other? Note which side is looser and which is tighter, relative to the other side.

Sacrotuberous Ligament



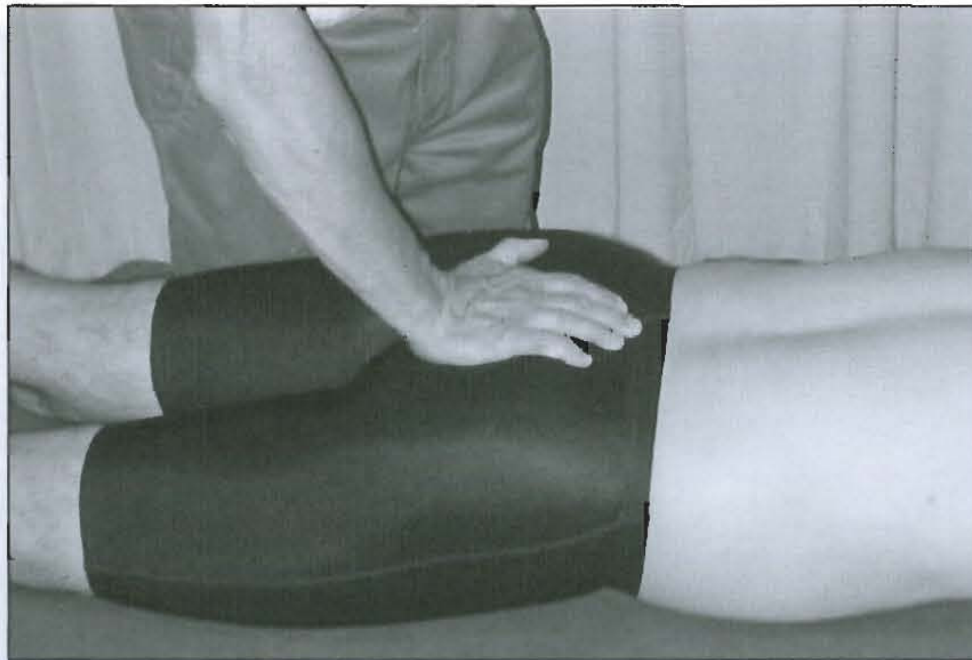L5

- Locate L5 transverse processes, bilaterally
- Place thumbs over L5 transverse processes, bilaterally
- Note relative positions of L5 transverse processes bilaterally
 - Which is anterior?
 - Which is posterior?
 - What is the preference of motion at L5 for Rotation?
- Record the Rotation of L5, Right, Left, or No Rotation
- **L5 rotates to the opposite side of sacrum and side bends to same side as the sacral axis motion**

Motion Tests for Sacral Diagnosis

Respiratory Motion Test

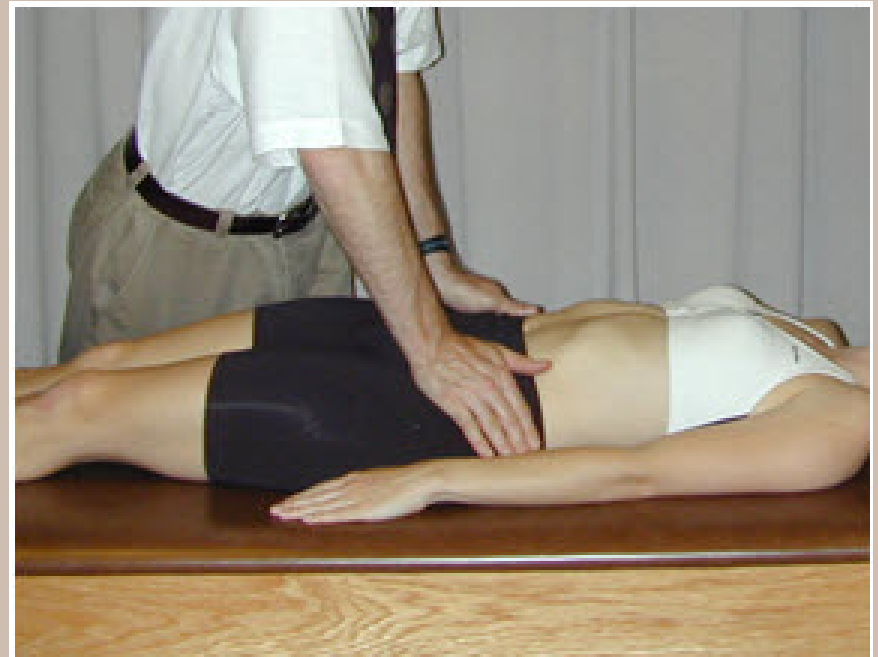1. With the patient prone, let your hand rest gently on the sacrum with fingertips at sacral base and palm at coccyx;
2. Ask the patient to take a deep breath and follow the sacrum into anatomical extension with inhalation and anatomical flexion with exhalation;
3. Restriction of sacral extension indicates flexion ease;
4. Restriction of sacral flexion indicates extension ease.



Respiratory motion testing of sacrum

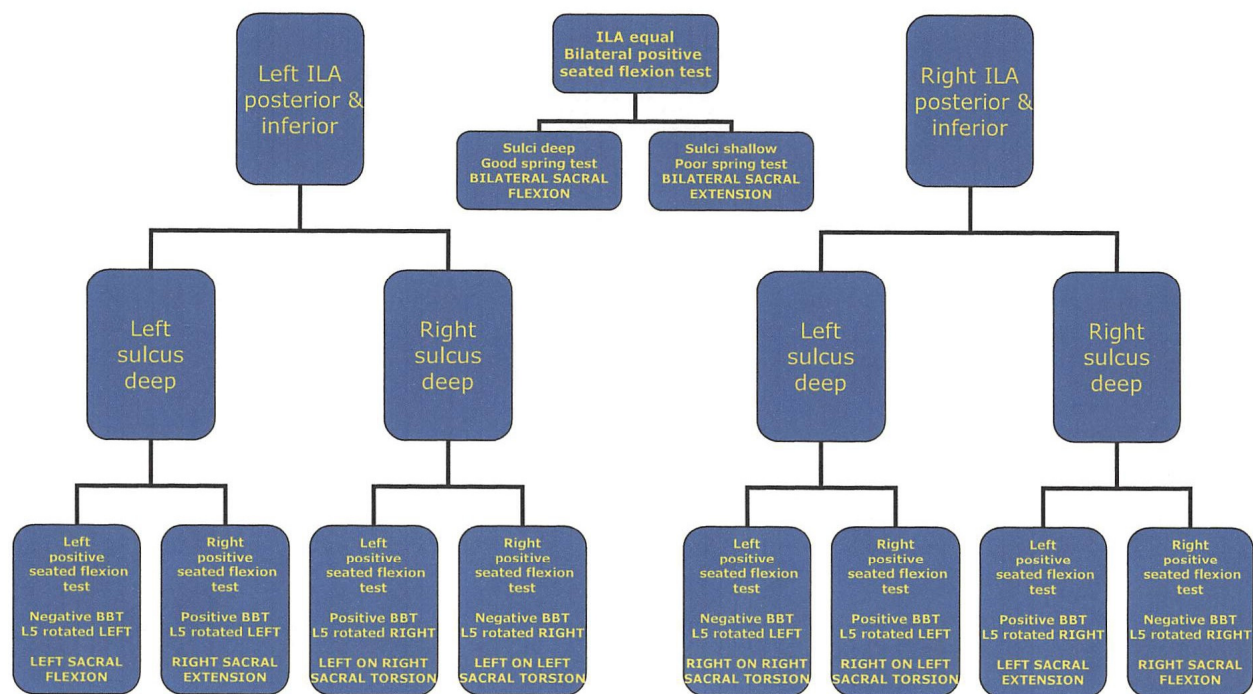
ASIS Compression Test

- Have the patient lie supine. The patient is then asked to raise his/her bottom up off the table and then set it back down again.
- Doctor Stands with head and shoulders centered over the patient.
- Contact the ASIS
 - Stabilize one ASIS while applying pressure at a 45 degree angle to the other ASIS
- Positive test - restricted movement of the Sacroiliac joint -> rock like motion
- Negative test - a sense of give or resilience => bounce or spring like motion



DIAGNOSIS
AND
TREATMENT
Of
SACRAL TORSIONS

Sacroiliac Dysfunction Algorithm



NCI, Paul R. Rennie, D.O., Jan 2006

Sacral Dysfunction Assessment

Are ILA's Symmetric Superior/Inferior?

Yes

No

Physiologic:
Oblique Axis:
Sacral Torsions

Non - physiologic:
Unilateral Sacral Shear
(Unilateral Sacral Flexion
And Extensions)

Is the Sacral Base Symmetric Anterior
/Posterior?

No

Yes

Sacral Base Posterior

Sacral Base Anterior

Sacral Margin Posterior
Upslipped Innominate

Neutral Sacrum


FRYETTE'S LAWS

- **Law I:** When the spine is in neutral, **sidebending to one side** will be accompanied by horizontal **rotation to the opposite side**. In **type I** somatic dysfunction, this law can be seen when more than one vertebrae are out of alignment and cannot be returned to neutral by flexion or extension. The involved group of vertebrae demonstrates a coupled relationship between side bending and rotation. When the spine is neutral, side bending forces are applied to a group of typical vertebrae and the entire group will rotate toward the opposite side: the side of produced convexity. Extreme type I dysfunction is similar to scoliosis.
- **Law II:** When the spine is flexed or extended (non-neutral), sidebending to one side will be accompanied by rotation to the same side. In **type II** somatic dysfunction of the spine, this law can be seen when only one vertebrae is out of place and becomes much worse on flexion or extension. There will be **rotation and sidebending in the same direction** when this dysfunction is present
- **Law III:** When motion is introduced in one plane it will modify (reduce) motion in the other two planes. Type III sums up the other two laws by stating dysfunction in one plane will negatively affect all other planes of motion

Lumbosacral Mechanics and Torsions

- Example L rotation on LOA
- Lumbar spine neutral: $S_L R_R$ (note in all torsions, L5 will rotate opposite of sacrum)
- N.B. this example is type 1- which go with Forward torsions as type II go with backward torsions
- Requires normal lordosis
- Occurs when (R) sacral base rotates anterior (“forward”) and does not rotate back (feels “springy”)
- left ILA posterior, & inferior

(i.e., taking a step forward on r leg)



Sacral Motion

In Neutral (type I) mechanics:
the sacral base moves *Anteriorly* and
rotates opposite to the rotation of L5 ;

Its axis motion is the SAME as the SB
side of L5 so :

Example: L5 RrSI causes a L on LOA, (L
on L) sacral torsion the R edge is
rotated L and anterior while the axis is
left so it = to the SB side of L5

Sacral Motion

In Non-Neutral (type 2) mechanics, the sacral base rotates *backwards*.

It is still opposite to the L5 rotation side and its axis is the same as the L5 SB side

Example: L5 RISI causes a R on LOA, the right sacral base moves *Posteriorly* while its axis side is Left and oblique

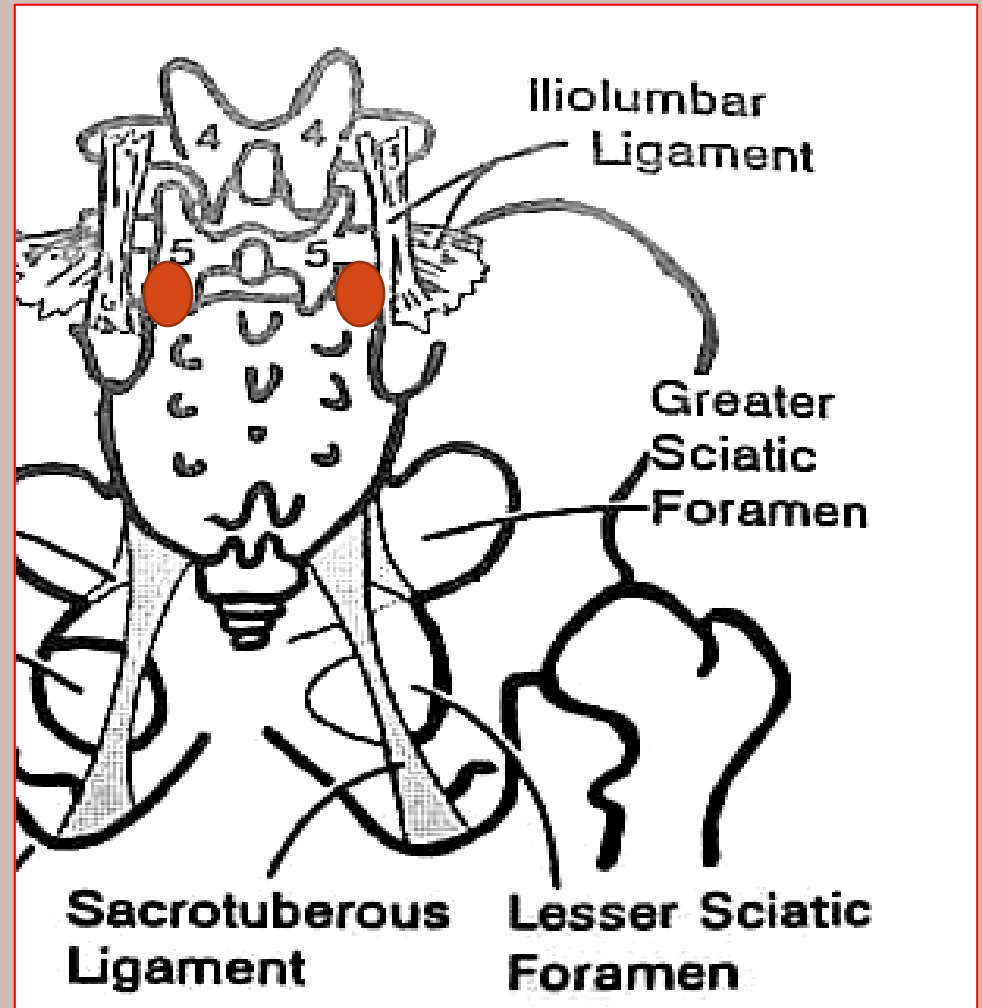
Sacral Torsion Rules

- A sacral torsion requires a deep sulcus and a posterior and inferior ILA to be on opposite sides

A deep right sulcus must have an posterior and inferior ILA on the Left by the above definition

Sacral Sulcus Depth

- Palpable groove just medial to PSIS.
- Space between sacral spines and lateral sacral crest.
- Place thumbs in inferior border of PSIS.
- Move ½-1” up and medial to PSIS.
- Push thumb tips on sacral base.
- Pads of thumbs are on ilium and tips on sacral base.
 - **Measure the depth of each sacral sulcus relative to opposite sulcus?**
 - **Record even, deep, or shallow, comparing one side to the other.**
 - **Both sides may be shallow or deep as well.**



○ **Sacral Torsion Rules**

- Name of lesion:
- Is for rotation and axis sides:
- R on R = right rotation on a right axis

R on L = right rotation on left axis

Sacral Torsion Rules

- **Rotation side** = the 1st of the 2 letters:
- L on L, or L on R, R on R, or R on L
- **The 1st Letter**
- Is also the *posterior or backward* edge of the sacral base
- Is the Short leg side
- Is the side of the posterior/ inferior ILA

Sacral Torsion Rules

The ***second letter*** (R on R) refers to the **Axis side** of the sacrum that is in play

Is the same as the side bent side of L5

Sacral Torsion Rules

- ***Seated flexion test*** is + on the side of the dysfunctional edge of the sacral base that is rotated either R or L *and* is either forward or backward
- The seated flexion test is the hallmark objective exam to determine your torsion diagnosis side and thus what edge to treat

Sacral Torsion Rules

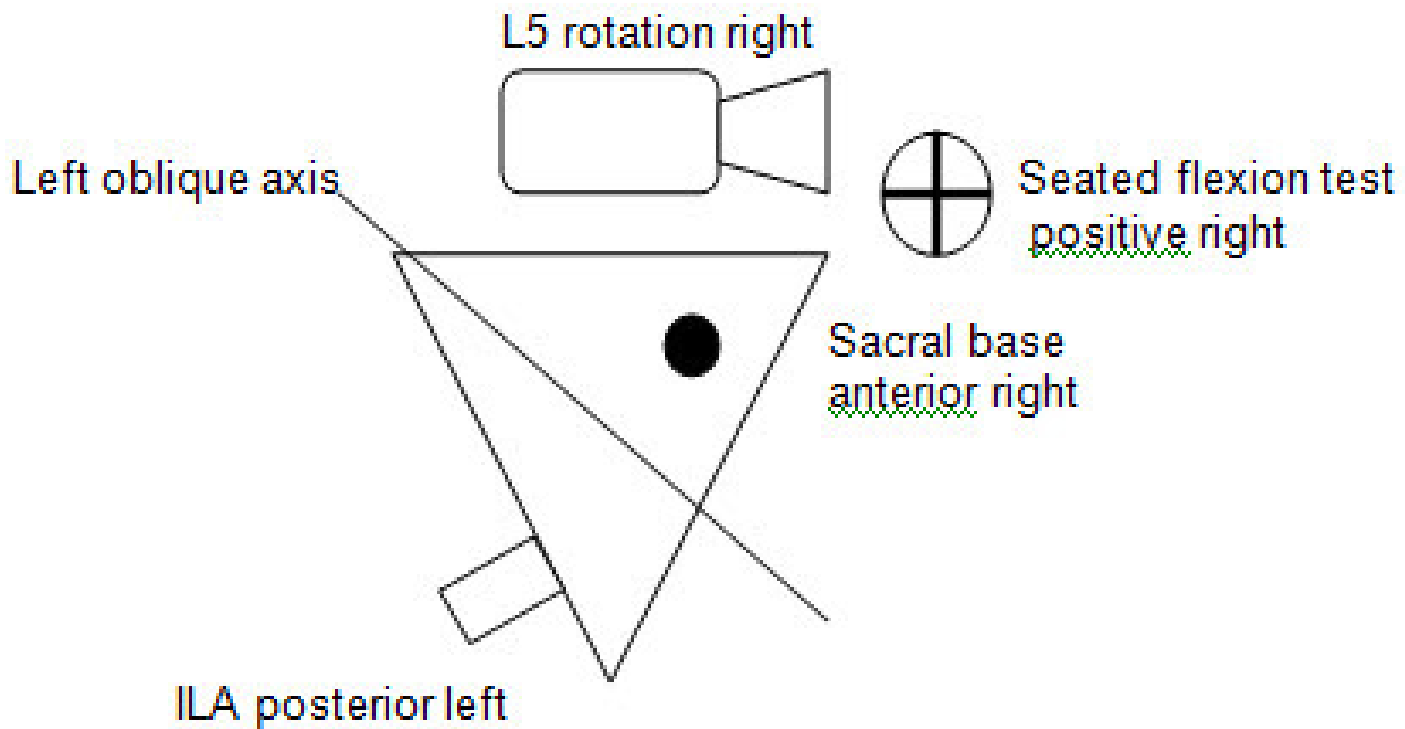
- L5 will be Convex to deep sulcus which
- = anterior edge

- Long leg on deep sulcus = anterior edge

- Forward lesions no + spring ; back ward lesions + spring

- **FORWARD TORSIONS**

KEY TO FIGURE: Findings for a left on left sacral torsion



Neutral - Left Oblique Axis Findings

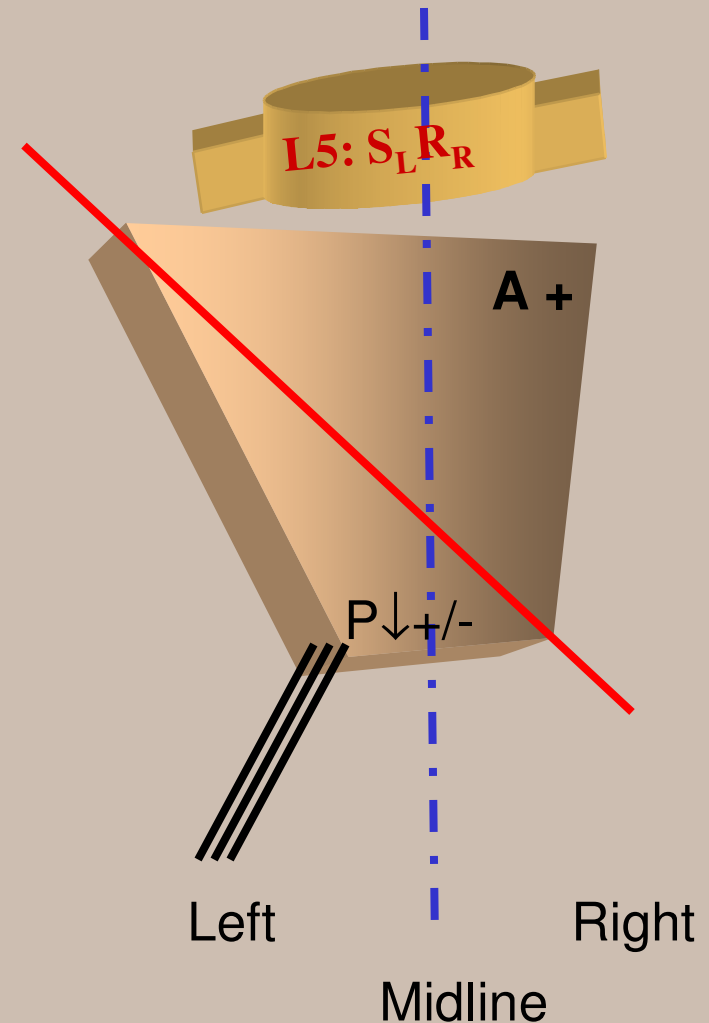
Name: L on LOA, R_L on LOA,

Landmarks – Static:

Sacral Base:	L posterior
Sacral Sulcus:	L shallow
ILA:	L Post/ Inf.
STL:	L Tight

Motion Testing:

Spring:	- (neg)
L5:	S _L R _R
Sacral Base	L - R +
ILA:	L +/- R +/-



Neutral - Right Oblique Axis Findings:

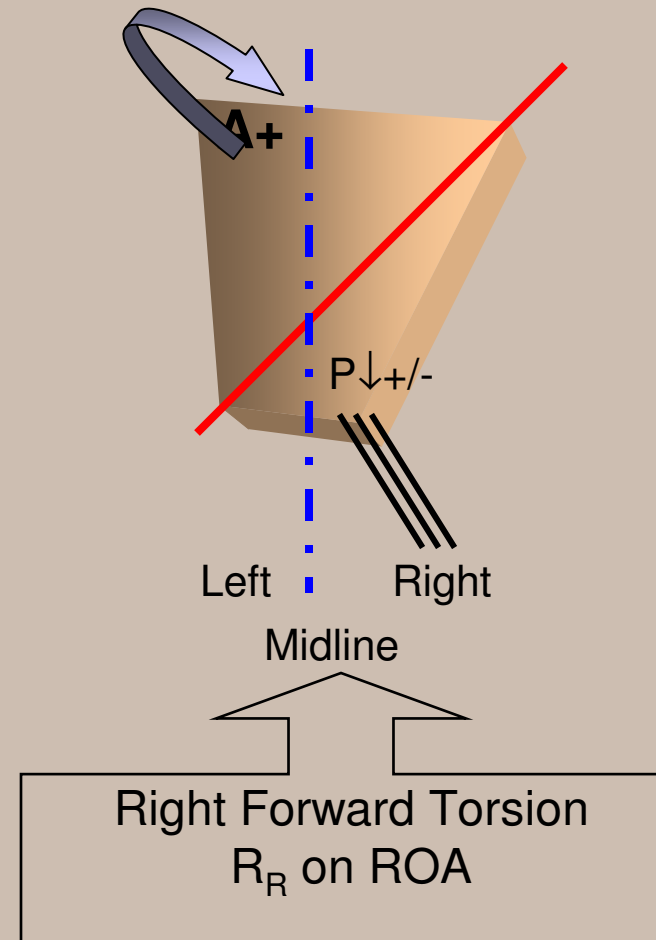
Name: R on ROA, R_R on ROA,

Landmarks – Static:

Sacral Base: R posterior
Sacral Sulcus: R shallow
ILA: R Post/Inf.
STL: R tight

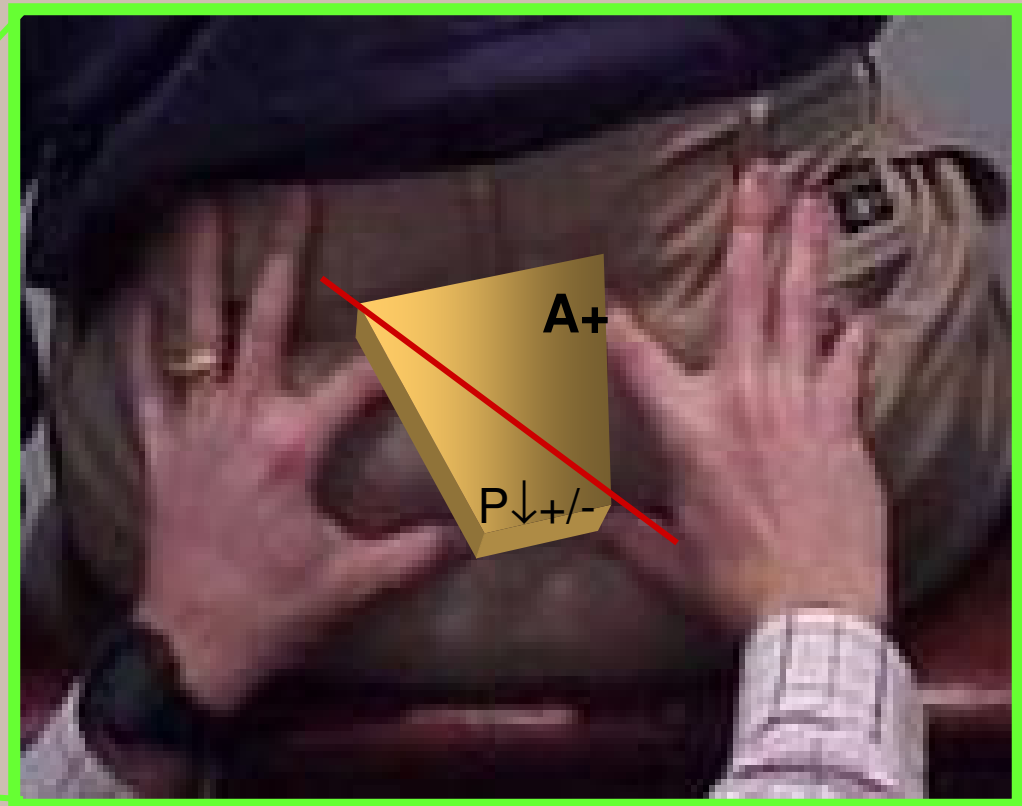
Motion Testing:

Spring: - (neg)
L5: S_RR_L
Sacral Base: L + R -
ILA: L +/- R +/-



Palpatory Experience

We can induce these **Neutral** diagnoses using the mechanics of the sacrum and spine... $SB_L \rightarrow L$ on **LOA**



SACRAL ROTATION ON THE SAME OBLIQUE AXIS

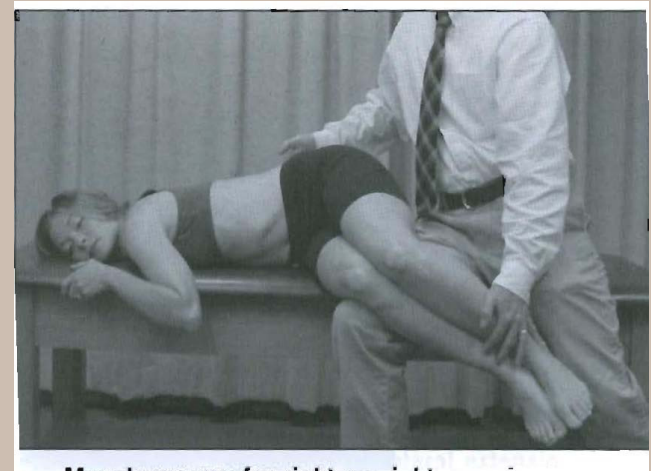
Diagnostic findings: (Sacrum rotated left on a left oblique axis, left on left, as an illustration)

- Tissue texture changes over the sacroiliac joints or in related musculature
- Right base anterior
- Right sulcus deep
- Left inferolateral angle is posterior and slightly inferior
- Left sacrotuberous ligament tight
- Motion of the right base is present
- Motion of the left ILA is restricted
- Motion at poles forming the left oblique axis (left base and right ILA) restricted
- Left rotation around the left oblique axis is present
- Right rotation around the left oblique axis is restricted
- Associated pelvic findings:
 - Right innominate is carried anterior by the sacrum
 - Right PSIS is superior
 - Left innominate is carried posterior by the sacrum
 - Left PSIS is inferior
 - Right medial malleolus may be inferior
 - L5 may be sidebent left and rotated right (left pelvic torsion)
- Tenderness to palpation over the sacroiliac joints

Forward Sacral Torsion ME

(a right on right sacral torsion)

1. Axis side down; chest on the table
2. Monitor at the lumbo-sacral junction
3. Flex the knees and hips until motion is felt at the lumbo-sacral junction
4. Support legs/knees with thigh or pillow
5. Apply pressure downward on lower legs/ankles
6. Ask patient to try to raise feet towards the ceiling while you resist
7. Rest
8. Re-engage barrier by repositioning ankles downward
9. Repeat 6, 7, 8
10. Recheck



Relative contra-indications-acute sacroiliac sprain, acute sacrum fracture, severe knee arthritis, deep venous thrombosis, or premature labor

HVLA FOR ANTERIOR SACRUM

Anterior Sacrum Leg Pull – HVLA (SDOFM 118 – 9.6)

Associated with forward sacral torsions, eg. L on L

1. Patient supine, physician stands at foot of table
2. Grasp patient's right ankle just Above malleoli with both hands.
3. Instruct patient to relax all muscles in low back and leg
4. Internally rotate leg to accumulate forces at Right Sacroiliac Joint (Gaps the SI joint)
5. Keep leg and thigh at level of table
6. Apply quick pull on leg, carrying right innominate anteriorly to meet sacrum (correcting the somatic dysfunction)
7. Recheck

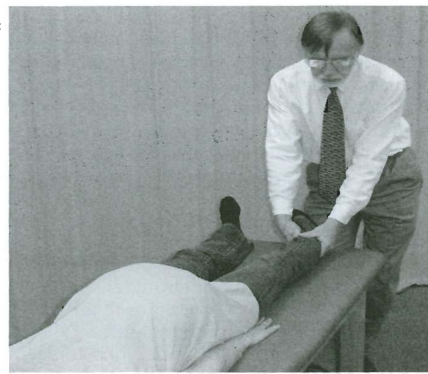


FIGURE 9.6 HVLA leg pull for anterior sacrum.

Contraindicated in knee instability

Posterior Sacrum Leg Pull – HVLA (SDOFM 119 – 9.7) Eg. Right Posterior Sacrum = Sacrum rotated Right on the Left Oblique Axis.

1. Patient supine, physician stands at foot of table
2. Grasp patient's right ankle just Above malleoli with both hands.
3. Instruct patient to relax all muscles in low back and leg
4. Internally rotate leg to accumulate forces at Right Sacroiliac Joint (Gaps the SI joint)
5. Keep the knee extended and flex hip until tension is felt on hamstrings
6. Apply final corrective force (quick pull on leg), carrying right innominate posteriorly to meet sacrum.
7. Recheck

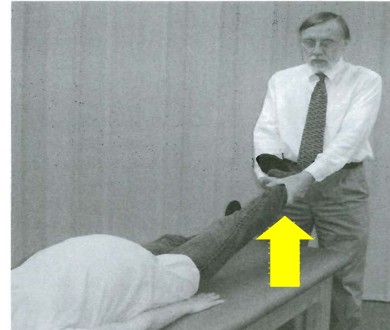


FIGURE 9.7 HVLA leg pull for a posterior sacrum.

Contraindicated in knee instability

POSTERIOR SACRAL

TORSIONS

SACRAL ROTATION ON THE OPPOSITE OBLIQUE AXIS

Diagnostic findings: (Sacrum rotated right on a left oblique axis, right on left, as an illustration)

- Tissue texture changes over the sacroiliac joints or in related musculature
- Right base posterior
- Right sulcus shallow
- Left inferolateral angle is anterior and slightly superior
- Left sacrotuberous ligament loose
- Motion of the left ILA is present
- Motion of the right base is restricted
- Motion at the poles forming the left oblique axis (left base and right ILA) is restricted
- Right rotation around the left oblique axis is present
- Left rotation around the left oblique axis is restricted
- Associated pelvic findings:
 - Right innominate is carried posterior by the sacrum
 - Right PSIS is inferior
 - Left innominate is carried anterior by the sacrum
 - Left PSIS is superior
 - Right medial malleolus may be superior
- Tenderness to palpation over the sacroiliac joints

Non-Neutral: Left Oblique Axis Findings (right on left sacral torsion)

Name: R on LOA, R_R on LOA,

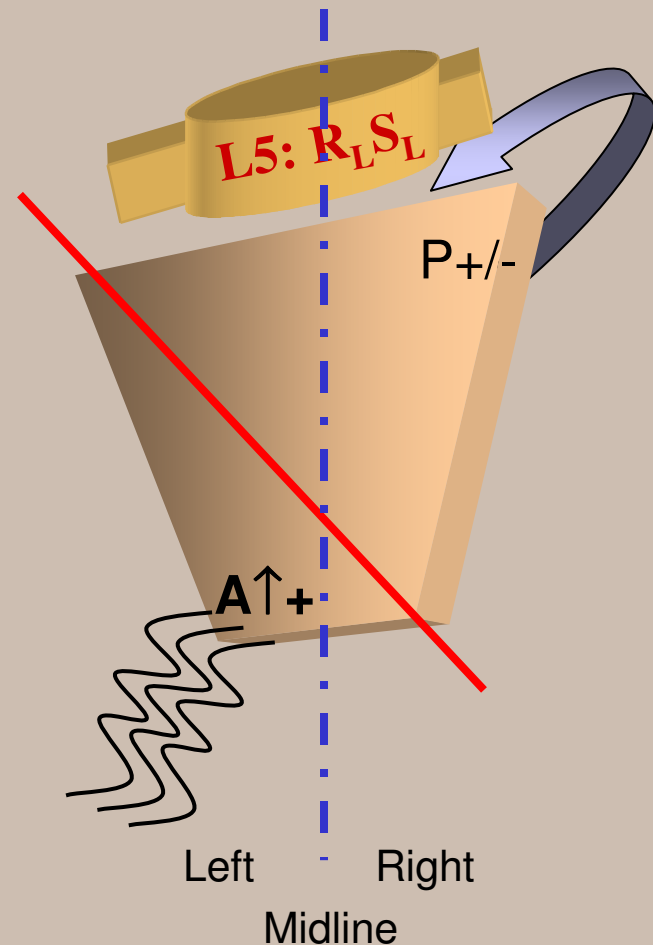
Landmarks – Static:

Sacral Base: L Anterior
Sacral Sulcus: L Deep
ILA: L Ant/ Sup
STL: L Loose

Motion Testing:

Spring: + (positive)
L5: R_LS_L
Sacral Base L - R +/-
ILA: L + R

+/-



Non-Neutral: Right Oblique Axis Findings (left on right sacral torsion)

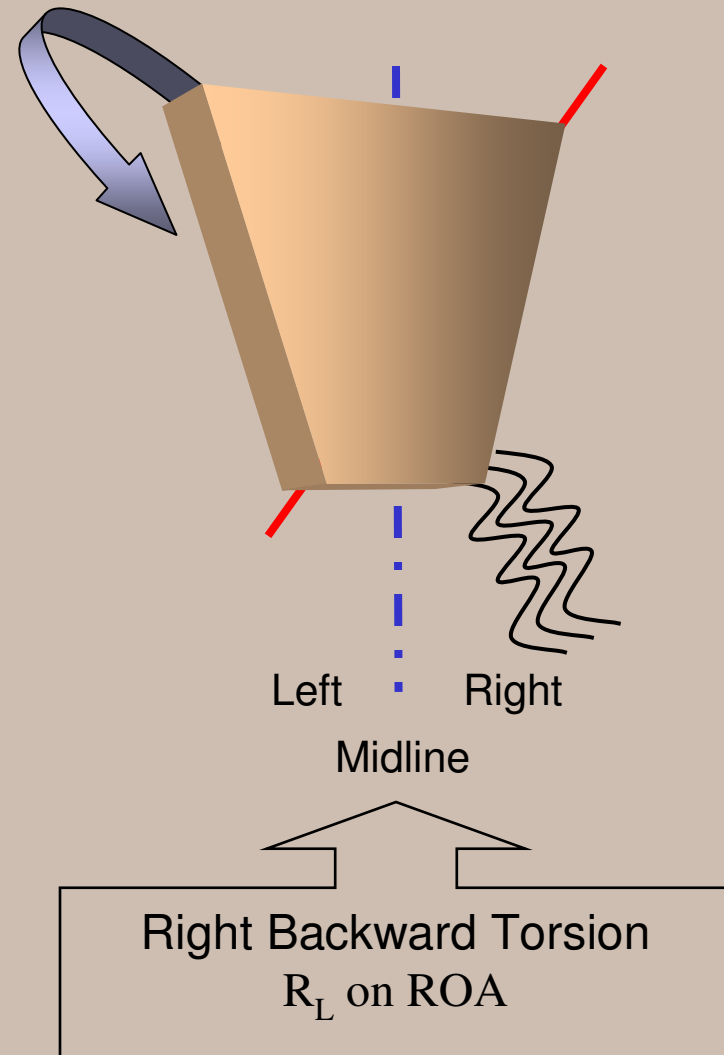
Name: L on ROA, R_L on ROA,

Landmarks:

Sacral Base: R Anterior
 Sacral Sulcus: R Deep
 ILA: R Ant./Sup.
 STL: R loose

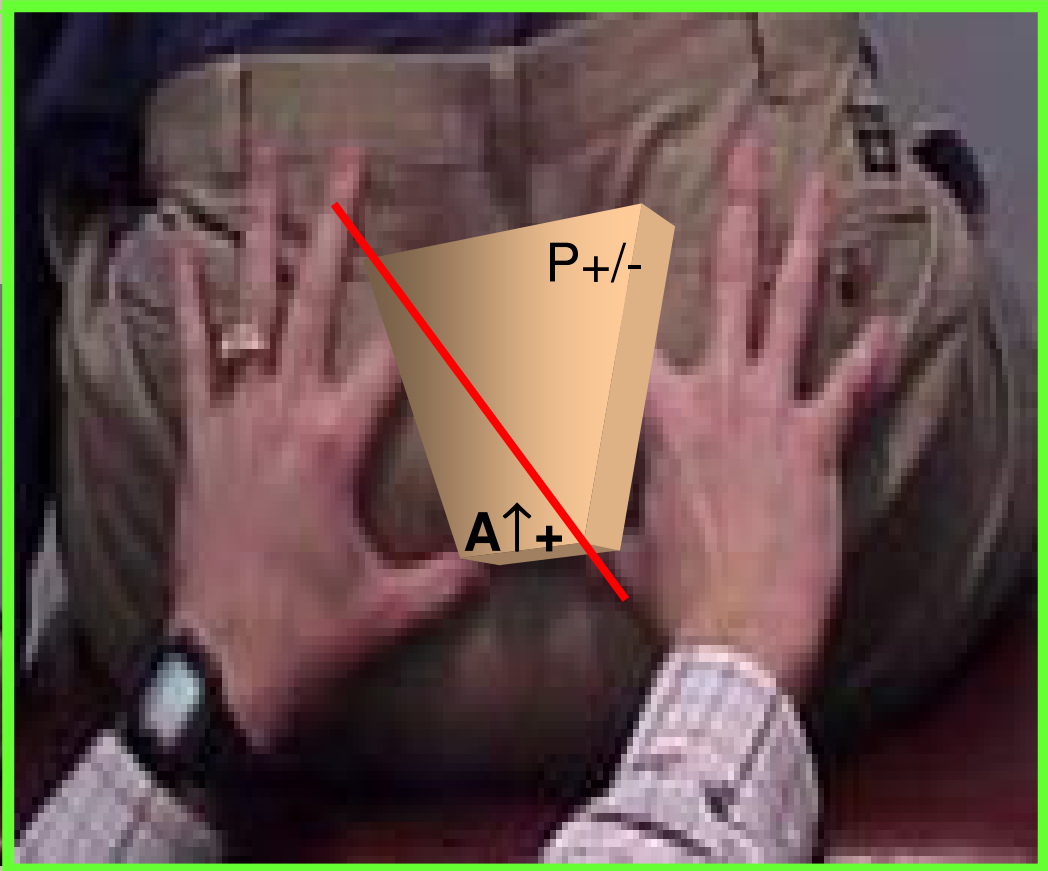
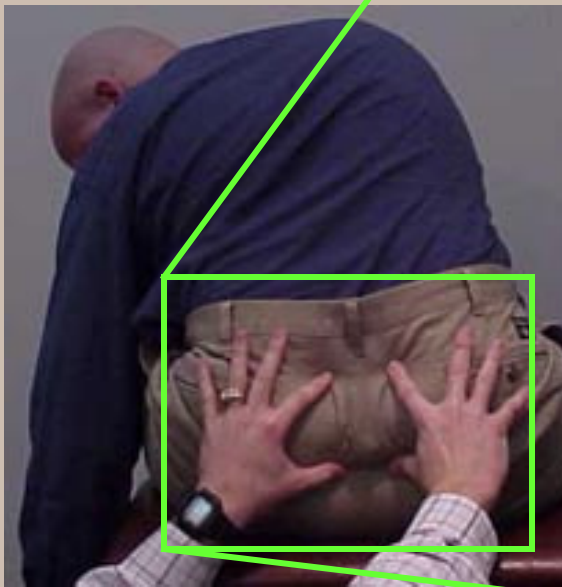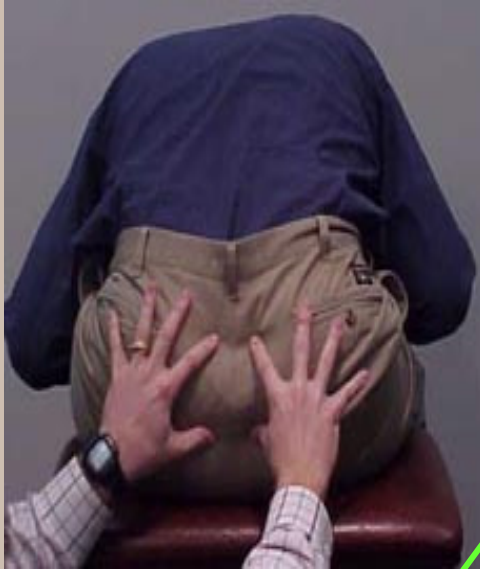Motion Testing:

Spring: +
 L5: R_RS_R
 Sacral Base: L +/- R -
 ILA: L +/- R +



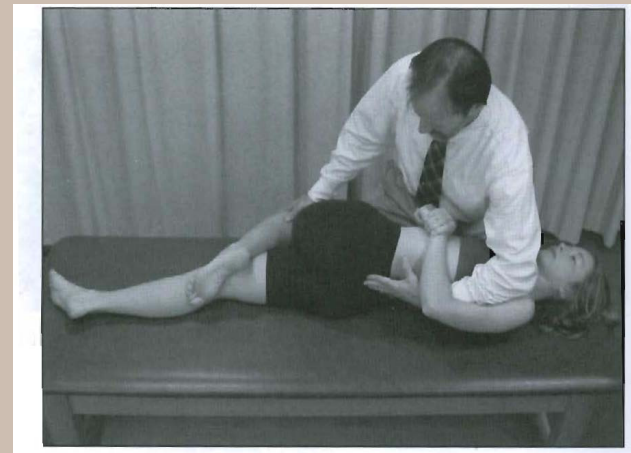
Palpatory Experience

We can induce these **Non-Neutral** diagnoses using the mechanics of the sacrum and spine... $SB_L \rightarrow R$



Backward Sacral Torsion Muscle Energy (left on right torsion)

1. Have the patient lie on the table axis side down
2. Monitor at the lumbosacral junction
3. Rotate the upper torso posteriorly until motion is felt at the lumbosacral junction
4. Hold the position of torso rotation
5. Flex the top leg until motion is felt at the lumbosacral junction; bend the knee and adduct the hip until motion is felt
6. Ask the patient to push their knee up towards the ceiling while you resist
7. Rest
8. Re-engage the barrier by adducting the knee/hip until motion is felt at the lumbosacral junction
9. Repeat 6, 7, 8
10. Recheck



Relative contraindications: acute sacroiliac sprain, acute sacrum fracture, severe hip arthritis, deep venous thrombosis, or premature labor

HVLA FOR POSTERIOR SACRUM

Anterior Sacrum Leg Pull – HVLA (**SDOFM 118 – 9.6**)

Associated with forward sacral torsions, eg. L on L

1. Patient supine, physician stands at foot of table
2. Grasp patient's right ankle just Above malleoli with both hands.
3. Instruct patient to relax all muscles in low back and leg
4. Internally rotate leg to accumulate forces at Right Sacroiliac Joint (Gaps the SI joint)
5. Keep leg and thigh at level of table
6. Apply quick pull on leg, carrying right innominate anteriorly to meet sacrum (correcting the somatic dysfunction)
7. Recheck

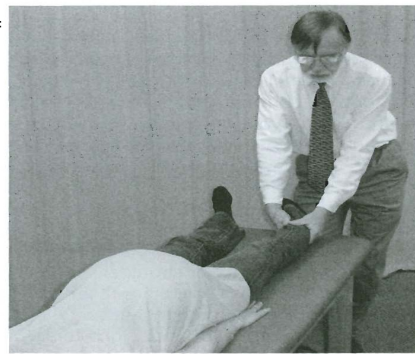


FIGURE 9.6 HVLA leg pull for anterior sacrum.

Contraindicated in knee instability

Posterior Sacrum Leg Pull – HVLA (**SDOFM 119 – 9.7**) Eg. Right Posterior Sacrum = Sacrum rotated Right on the Left Oblique Axis.

1. Patient supine, physician stands at foot of table
2. Grasp patient's right ankle just Above malleoli with both hands.
3. Instruct patient to relax all muscles in low back and leg
4. Internally rotate leg to accumulate forces at Right Sacroiliac Joint (Gaps the SI joint)
5. Keep the knee extended and flex hip until tension is felt on hamstrings
6. Apply final corrective force (quick pull on leg), carrying right innominate posteriorly to meet sacrum.
7. Recheck

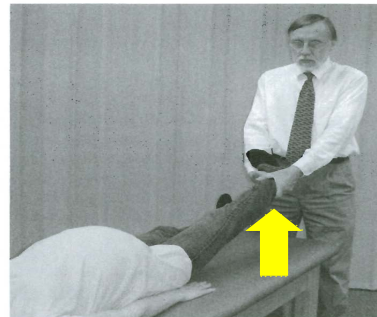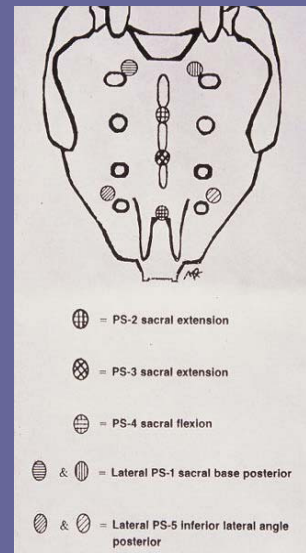
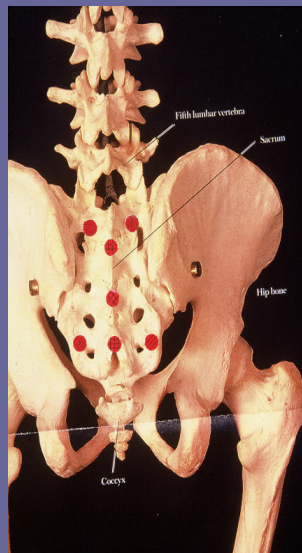


FIGURE 9.7 HVLA leg pull for a posterior sacrum.

Contraindicated in knee instability

ORIGINAL COUNTERSTRAIN SACRAL TENDERPOINTS

Sacrum



- The tender points are probably in the area of attachment of the
- multifidus, spinalis, longissimus, iliocostalis muscles & overlying fascia

COUNTERSTRAIN FOR SACRAL TORSION (not the same as counterstrain for the sacrum)

- Paper published by Ramirez in JAOA Vol 91 No 3 March 1991 described the following:
- Both anterior and backward sacral torsions were treated by:
- 1) noting the side of the tender sacral foramina – (will be the **same as the axis side** of the torsion)
- 2) sitting on **opposite side** of the tender points and abducting prone patient's leg 30 degrees off table and flexing hip to rest on your thigh
- 3) pushing anteriorly on **ipsilateral PSIS** with operator's forearm for 90 seconds

SOURCES AND RESOURCES

- KIMBERLY MANUAL-2006 EDITION
- POCKET MANUAL OF OMT-2ND EDITION
- PRINCIPLES OF MANUAL MEDICINE-GREENMAN
- OMT REVIEW-SAVARESE-3RD EDITION
- LECTURES FROM OMM FACULTY – A.T.STILL
UNIVERSITY-PHOENIX AZ- WITH PERMISSION
- LECTURES FROM DR.HARMON MYERS
- JAOA Vol 91 No 3 March 1991

THANK YOU



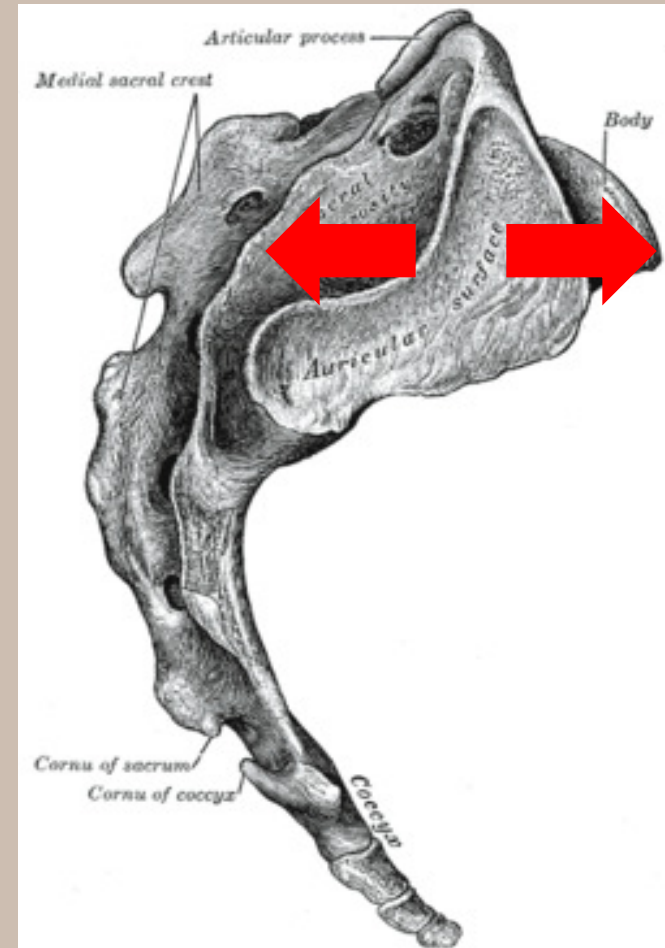


SACRAL SHEARS

ILAs are inferior and posterior on same side of deep sulcus
– which distinguishes this from a torsion

Sacral Shears

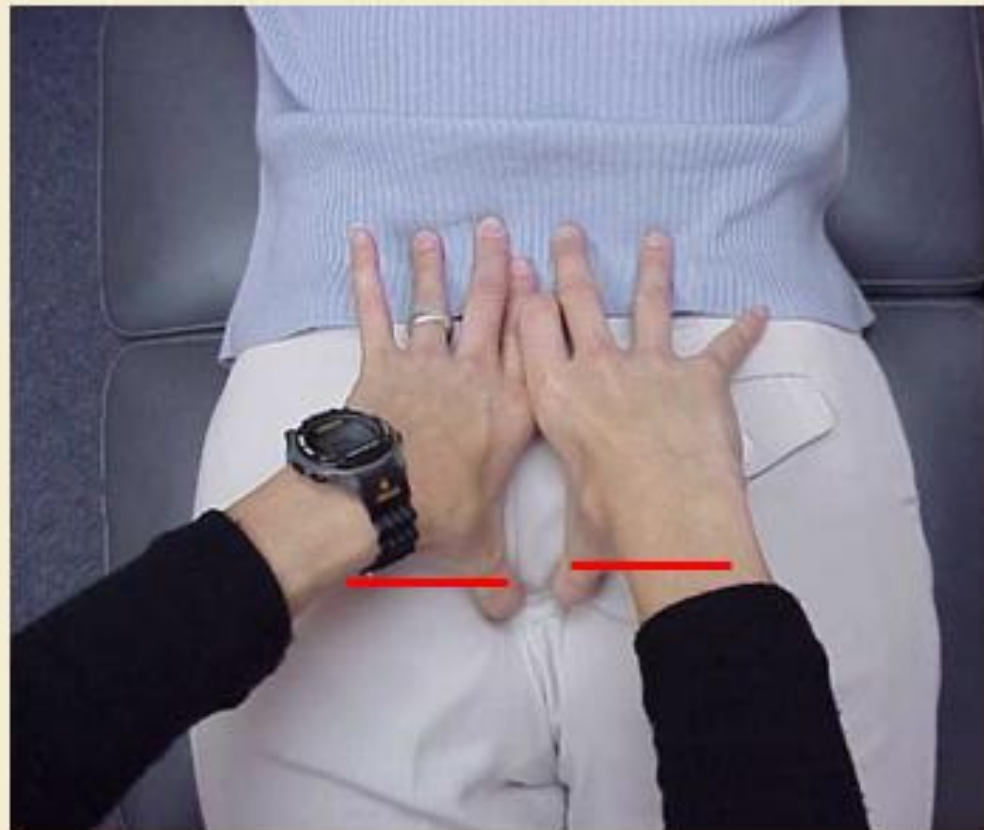- Produced when the sacrum shifts forward within the sacroiliac joint.
- Two Types:
 - Unilateral Sacral Flexion
 - Unilateral Sacral Extension
- Sx: Chronic low back pain.



Findings for Sacral Shear

- The distinct finding of the static landmarks that indicates a sacral shear is:

Markedly Inferior ILA
(on the lateralized side)

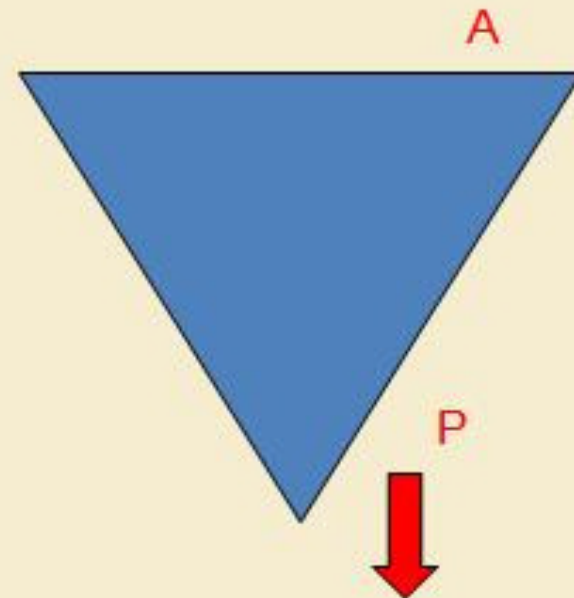


Left sacral shear

Findings for Sacral Shear

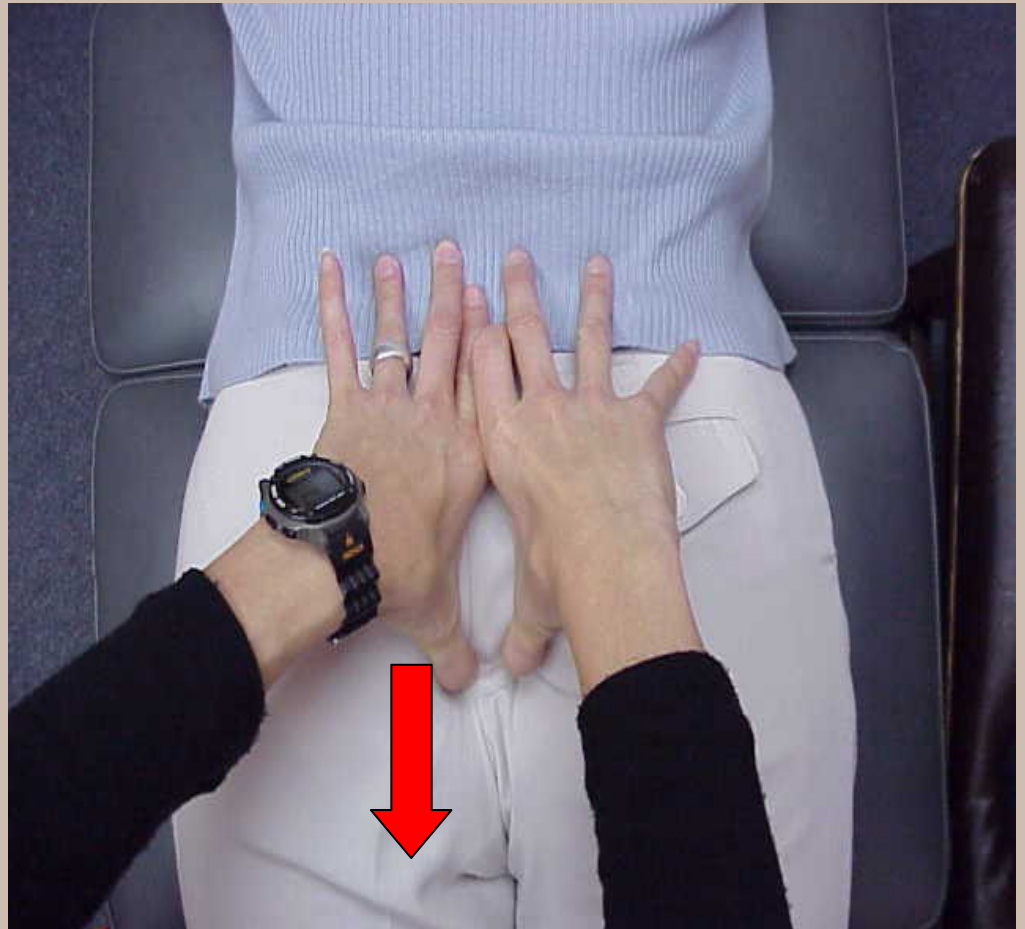Static examination

- The sacral base on the side of the inferior ILA will generally be anterior
- The markedly inferior ILA will also be posterior (anatomically, it has to be)
- Sacral sulcus will be **deep** if the innominates are normal but may be shallow if the innominate is also rotated anterior.



Naming the Shear

- The shear is named for the side of the inferior ILA..
The sulcus is deep on same side- (which distinguishes this from a torsion)
The seated flexion positive side will tell you how to interpret whether it is a unilateral flexion or extension,
i.e.,sulcus deep and ILA on R with R seated flexion + =
R unilateral Flexion;
L unilateral extension if seated is + L with the same findings of: deep sulcus R and ILA post/inf R

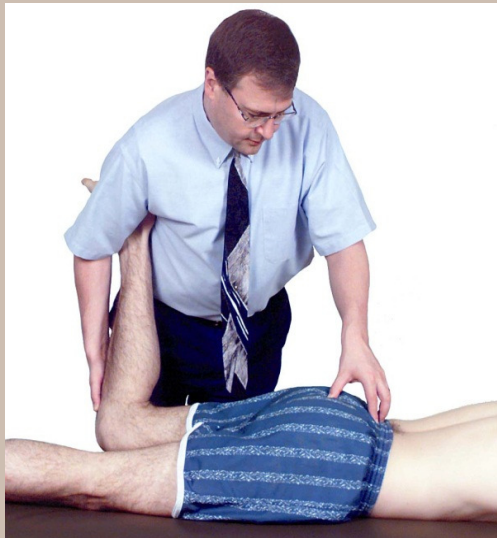

UNILATERAL SACRAL FLEXION (SACRAL SHEAR)

Diagnostic findings: (Left unilateral sacral flexion as an illustration)

- Tissue texture changes over the sacroiliac joints
- Iliac crests are level
- Left base is anterior
- Left sulcus is deep
- Left ILA is substantially inferior
- Left ILA is slightly posterior
- Left sacrotuberous ligament is loose
- ASIS compression test is positive on the left
- Motion of the left base is present but limited
- Motion of the left ILA is restricted
- Motion of the right base and ILA may be altered
- Tenderness to palpation over the sacroiliac joints

Springing Respiratory Force Left Unilateral Sacral Flexion A



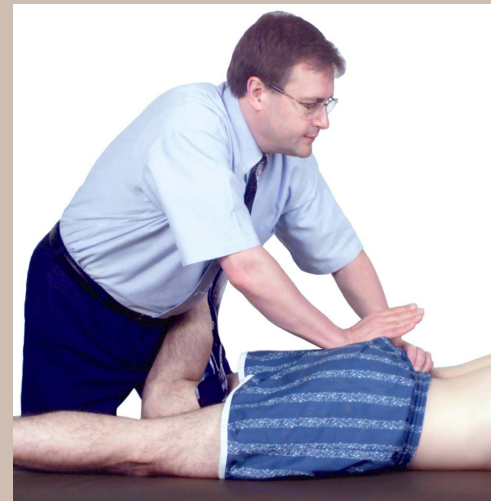Monitor at PSIS

Abduct and internally rotate LE
until motion is felt.

Maintain that position by leaning of
the patient's femur/leg

Springing Respiratory Force Left Unilateral Sacral Flexion B

1. Contact left ILA and apply superior and anterior pressure
2. Have the patient take a deep breathe in and hold (encourages sacral base to move posteriorly)
3. Spring anteriorly and superiorly while patient is holding breath
4. Exhale while physician maintains gain in position
5. Repeat steps 2, 3, 4
6. Recheck



UNILATERAL SACRAL EXTENSION

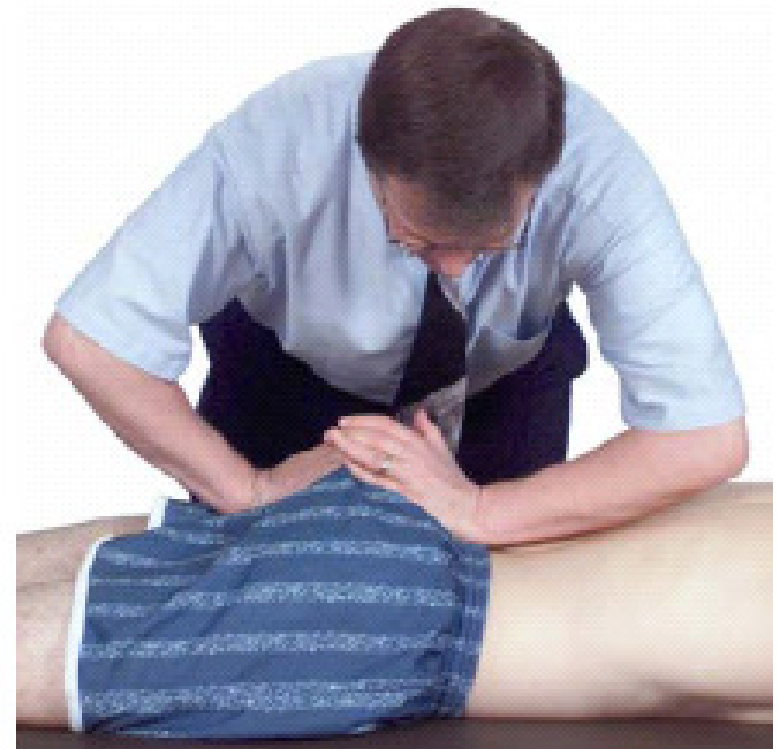
Diagnostic findings: (Left unilateral sacral extension as an illustration)

- Tissue texture changes over the dysfunctional sacroiliac joint
- Iliac crests are equal
- Left base is posterior
- Left ILA is substantially superior
- Left ILA is slightly anterior
- Left sulcus is shallow
- Left sacrotuberous ligament is loose
- ASIS compression test is positive on the left
- Motion of the left base is restricted
- Motion of the left ILA is present but limited
- Motion of the right base and ILA may be altered
- Tenderness to palpation over the sacroiliac joints











A. Prone--direct method—LVMA (springing) (4527.11A)

Diagnosis: Left unilateral sacral extension

1. Patient is prone and the physician stands at the side of the table
2. Physician places the heel of the caudad hand on the inferior aspect of the ischial tuberosity and the hypothenar eminence of the other hand on the sacral base
3. Physician carries the ischial tuberosity superiorly and the sacral base anteriorly and inferiorly to the restrictive barrier
4. Low velocity, moderate amplitude springing is applied directing both hands toward each other
5. Recheck



THE GOLDEN OPP SACRUM DX REFERENCE (M. Christensen/ Edited by Dr. Heath)

SACRAL TORSIONS*				
Forward	L on L -R Sulcus Deep (L Shallow) -L ILA Posterior/Inferior -Pos. R Seated Flexion Test -Neg. Lumbosacral Spring Test		R on R -L Sulcus Deep (R Shallow) -R ILA Posterior/Inferior -Pos. L Seated Flexion Test -Neg. Lumbosacral Spring Test	
	Backward	L on R -L Sulcus Shallow (R Deep) -R ILA Anterior/Superior -Pos. L Seated Flexion Test -Pos. Lumbosacral Spring Test		R on L -R Sulcus Shallow (L Deep) -L ILA Anterior/Superior -Pos. R Seated Flexion Test -Pos. Lumbosacral Spring Test
*Blue arrows indicate motion preference. (Ex. R on R- Left base will move anterior and Right ILA will move posterior and inferior.)				
	L Margin Posterior -L Sulcus Shallow -L ILA shallow -Anterior motion L side restricted. -Anterior motion R side present.		R Margin Posterior -R Sulcus Shallow -R ILA shallow -Anterior motion R side restricted. -Anterior motion L side present.	
	Bilateral Flexion -R & L Sulci Deep -Bilateral ILAs Shallow -Neg. Lumbosacral Spring Test		Bilateral Extension -R & L Sulci Shallow -Bilateral ILAs Deep -Pos. Lumbosacral Spring Test	
SHEARS**				
Flexion	Unilateral Flexion Right -R Sulcus Deep -R ILA Posterior/Inferior -Pos. R Seated Flexion Test -Neg. Lumbosacral Spring Test		Unilateral Flexion Left -L Sulcus Deep -L ILA Posterior/Inferior -Pos. L Seated Flexion Test -Neg. Lumbosacral Spring Test	
	Extension	Unilateral Extension Right -R Sulcus Shallow -R ILA Superior/Anterior -Pos. R Seated Flexion Test -Pos. Lumbosacral Spring Test		Unilateral Extension Left -L Sulcus Shallow -L ILA Superior/Anterior -Pos. L Seated flexion -Pos. Lumbosacral Spring Test

**Shears will have greater superior/inferior motion than anterior/posterior.

**Key: "v" = " indicates posterior position.

Lumbosacral Spring Test	
Negative (IT SPRINGS!)	Positive (It DOES NOT Spring!)
-Forward Torsion (R on R, L on L)	-Backward Torsion (R on L, L on R)
-Unilateral Flexion	-Unilateral Extension
-Bilateral Flexion	-Bilateral Extension

-Note: LS is considered neutral if you are able to Spring!

SOURCES AND RESOURCES

- KIMBERLY MANUAL-2006 EDITION
- POCKET MANUAL OF OMT-2ND EDITION
- PRINCIPLES OF MANUAL MEDICINE-GREENMAN
- OMT REVIEW-SAVARESE-3RD EDITION
- LECTURES FROM OMM FACULTY – A.T.STILL UNIVERSITY-PHOENIX AZ- WITH PERMISSION
- LECTURES FROM DR.HARMON MYERS

THANK YOU

Upslip innominate(pubic shear)

• UPSLIP INNOMINATE

- **Diagnose:** L iliac crest superior
- L ischial tuberosity is superior
- L medial malleolus is superior
- L base is anterior so sulcus may be Deep
- L ILA may be posterior **but ILAs are =**
- Seated flexion + L
- ASIS compression is + L
- Motion restricted at L base and ILA
- Tender at S/I joint

Upslip treatment

Superior Iliac/Pubic Shear

Place pressure pad caudad to ipsilateral ILA to help restrict caudad motion of the sacrum

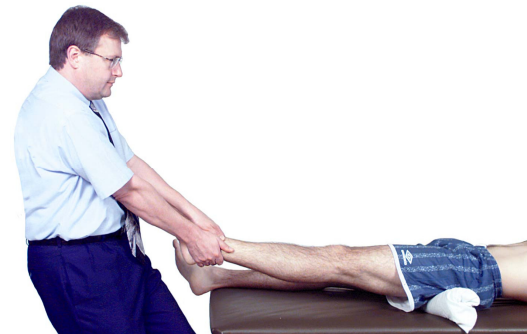Abduct and internally rotate to gap the ipsilateral SI joint

Have the patient take a deep breath and hold (encourages sacral base to move posteriorly)

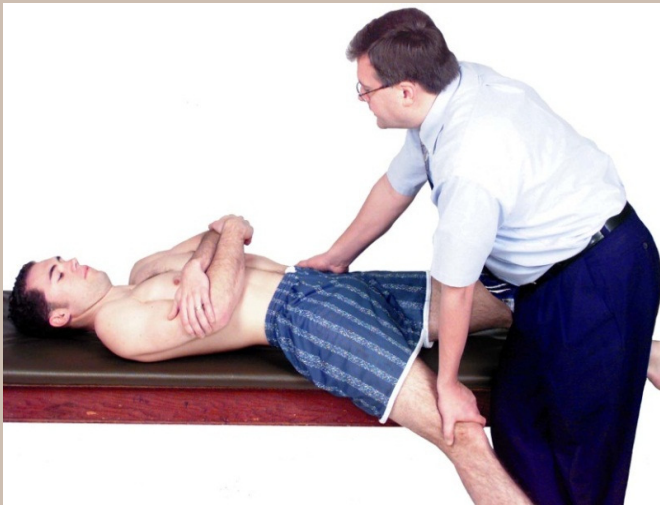Tug along the long axis of the lower extremity

Release

Recheck

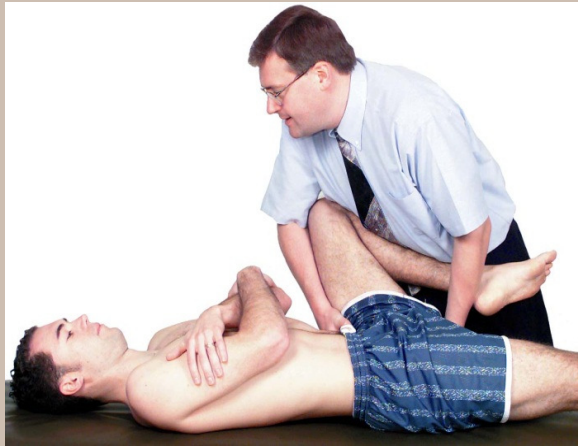

Muscle Energy Superior Pubic Shear



1. Patient supine with dysfunctional side towards the edge of the table
2. Monitor opposite ASIS
3. Extend hip until motion is felt at the monitoring hand
4. Ask the patient to pull knee up while you resist
5. Relax
6. Re-engage extension
7. Repeat 4, 5, 6
8. Recheck

Muscle Energy Inferior Pubic Shear

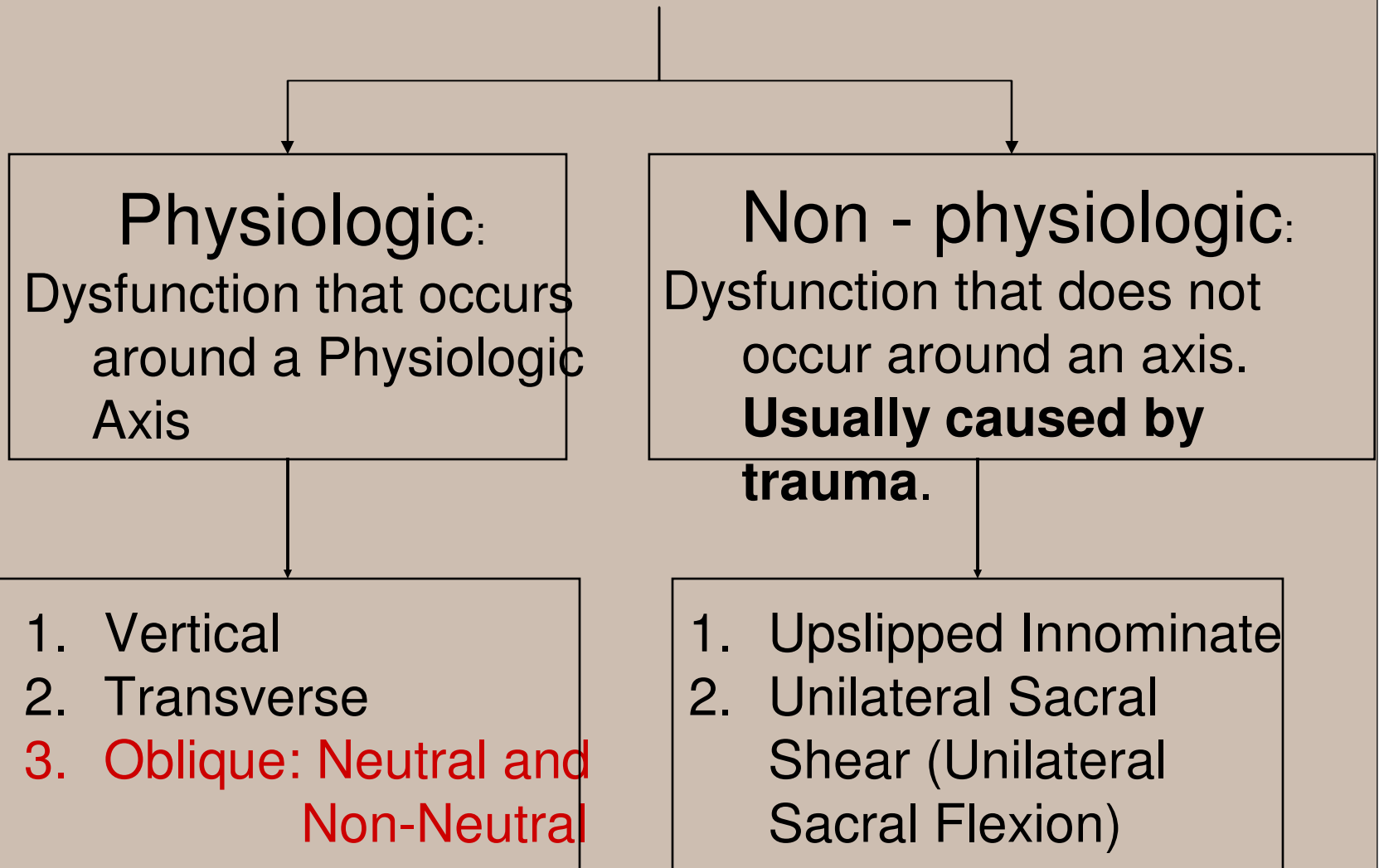


Posterior Iliac rotation carries
pubic ramus superiorly

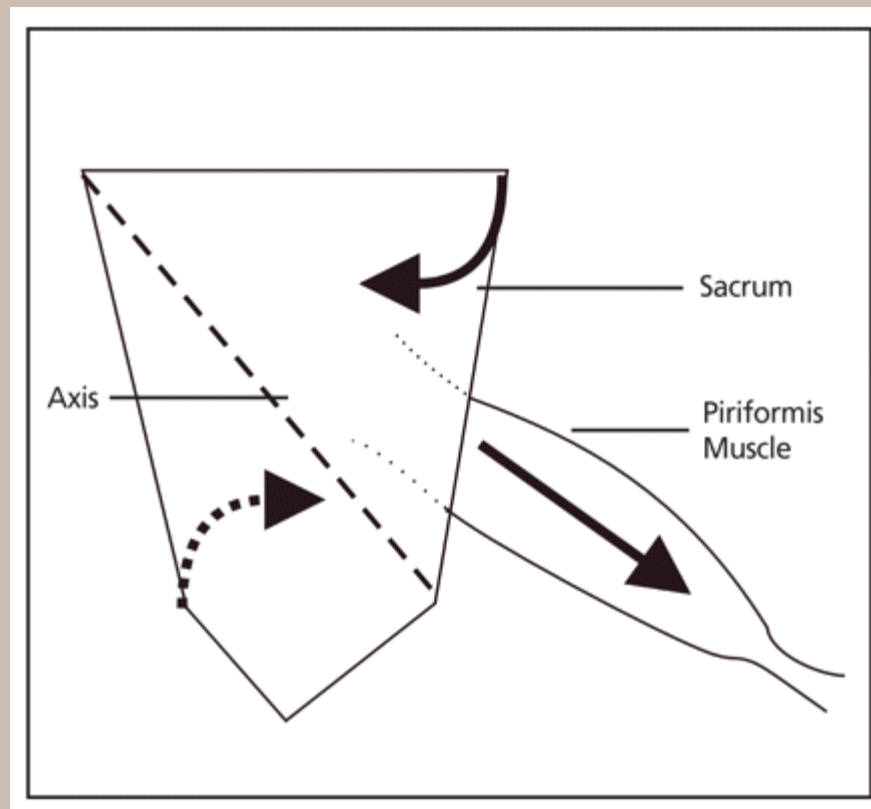
1. Monitor ipsilateral ASIS
2. Flex and abduct the hip
3. Contact ischial tuberosity
4. Posteriorly rotate the hip with pressure on the ASIS, ischial tuberosity, and knee
5. Have the patient attempt to straighten the leg while you resist
6. Relax
7. Re-engage rotation
8. Repeat 5, 6, 7
9. Recheck

Sacral Somatic Dysfunction

(AKA Sacroiliac Dysfunction)



Piriformis Movement



SACRAL MARGIN POSTERIOR (HORIZONTAL PLANE - VERTICAL AXIS)

Diagnostic findings:

- Tissue texture changes over the sacroiliac joints and related musculature
- PSIS's are level
- ILA's are level superiorly/inferiorly
- Tenderness to palpation over the sacroiliac joints and related musculature

Sacrum, rotated around a midline vertical axis

- On the posterior side
 - entire sacral margin is posterior
 - base is posterior
 - ILA is posterior
 - sulcus is shallow
 - sacrotuberous ligament is tight
 - anterior springing at the superior and inferior poles is restricted
- On the anterior side
 - entire sacral margin is anterior
 - base is anterior
 - ILA is anterior
 - sulcus is deep
 - sacrotuberous ligament is relaxed
 - anterior springing at the superior and inferior poles is present

The only Vertical Axis Diagnosis is...

Name: Sacral Margin Posterior

For **Left** Sacral Margin Posterior:

Landmarks:

Sacral Base: L Posterior

Sacral Sulcus: L Shallow

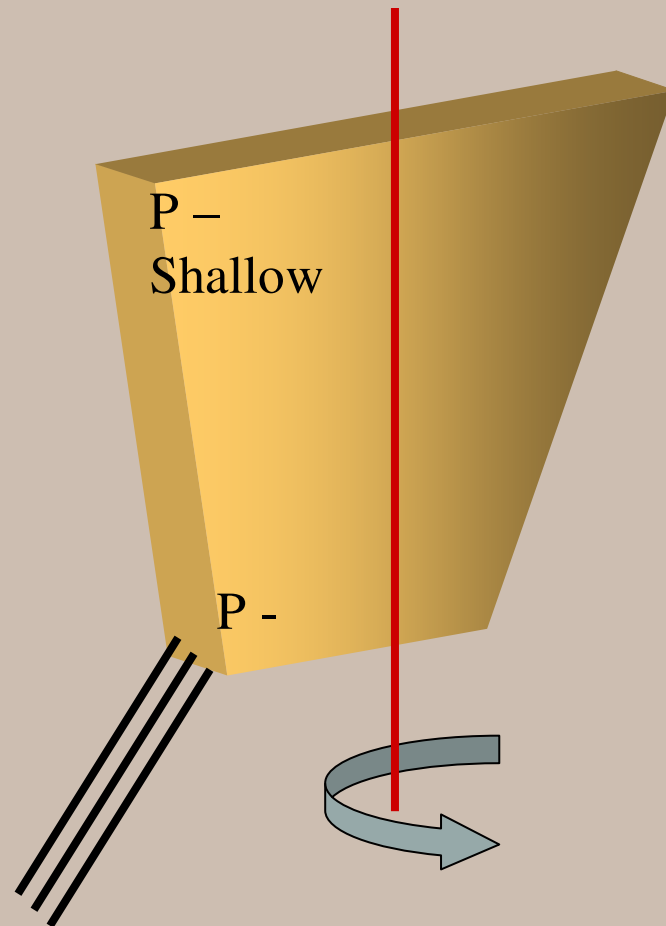
ILA: L Posterior

STL: L Tight

Motion:

Sacral Base: L -

ILA: L -



Sacral Margin Posterior cont...

For **right** sacral margin posterior:

Landmarks:

Sacral Base: R posterior

Sacral Sulcus: R shallow

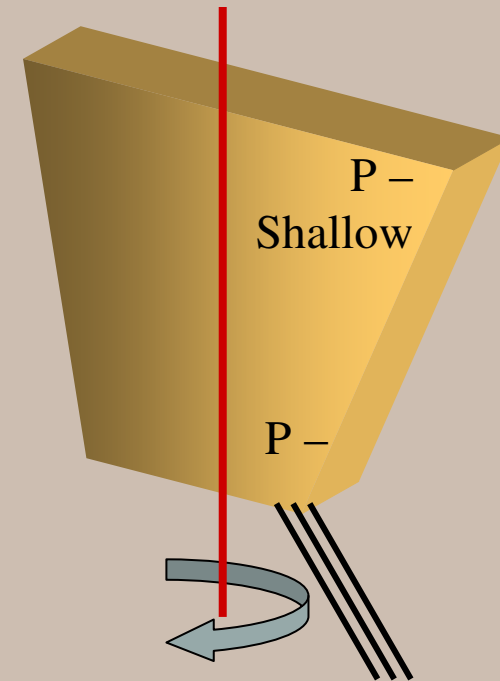
ILA: R posterior

STL: R tight

Motion:

Sacral Base: R -

ILA: R -



Right Sacral Margin Posterior

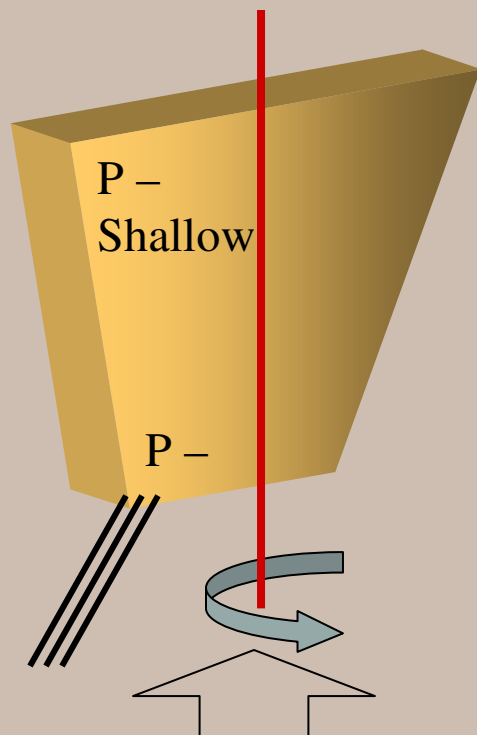
Sacral Margin Posterior:

(ILA's are level superiorly/inferiorly)

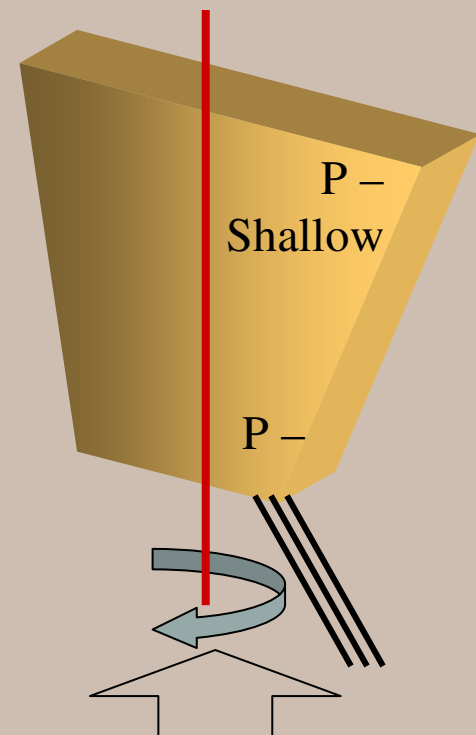
On the posterior side:

- Entire sacral margin is posterior
 - Base is posterior
 - ILA is posterior
 - Sulcus is shallow
 - Sacrotuberous ligament is tight
 - Anterior springing at the superior and inferior poles is restricted

Sacral Margin Posterior can occur on either side of a Vertical axis, but it is always named for the posterior side!

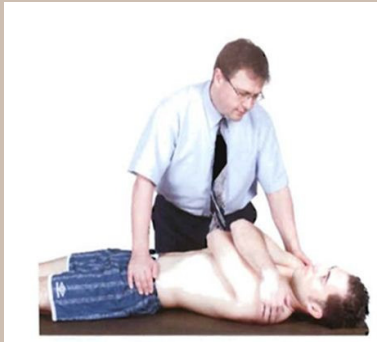

Left Sacral Margin Posterior



Right Sacral Margin Posterior

HVLA Posterior Sacral Margin



Stand on side opposite the posterior margin

Sidebend the patient away from you

Stabilize the ASIS on the posterior margin side

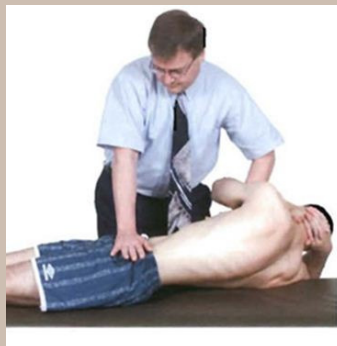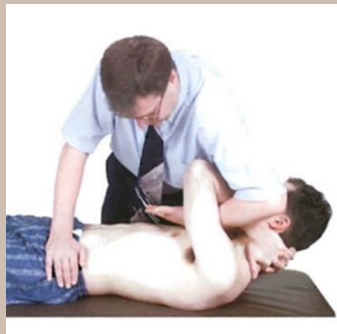Have patient clasp hands behind neck

Place cephalad arm through the space created by the patient's arm and rest on sternum

Rotate the patient towards you (spine and sacrum) until tension is felt at the stabilizing ASIS

HVLA thrust is applied posteriorly through the ASIS

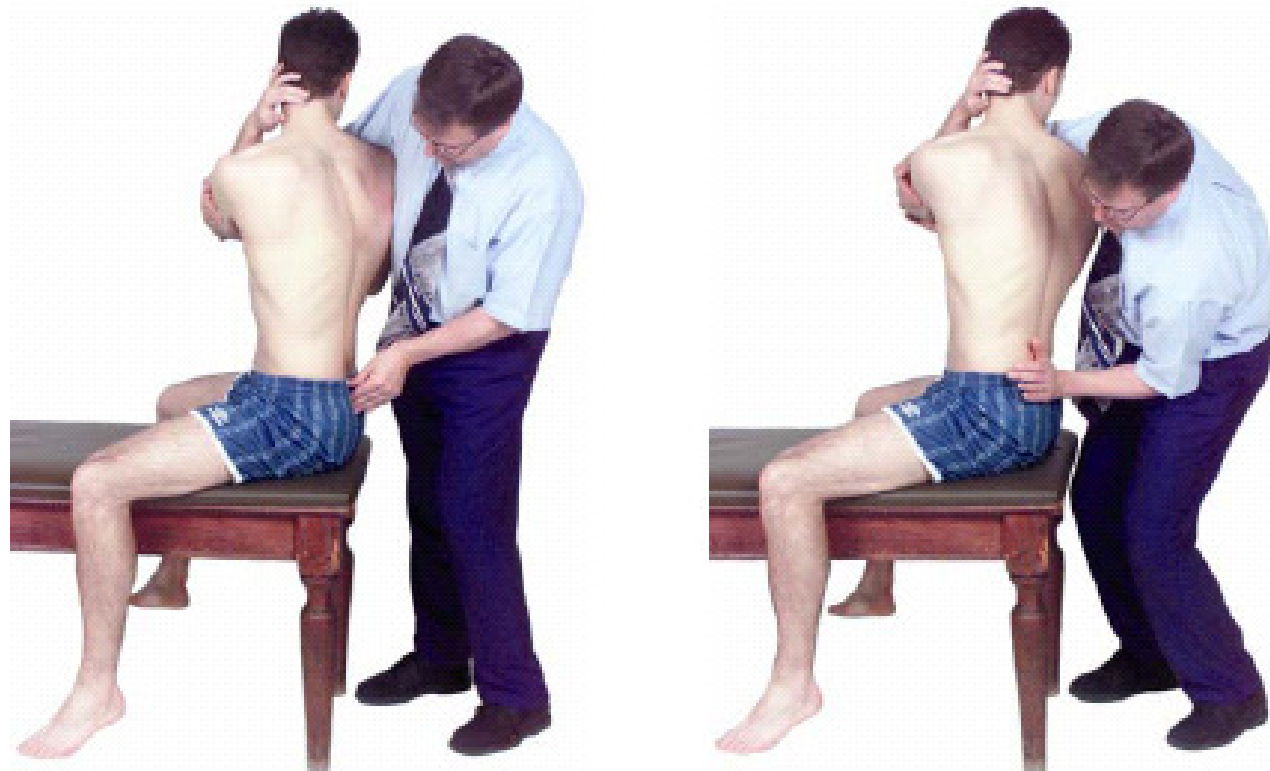Recheck

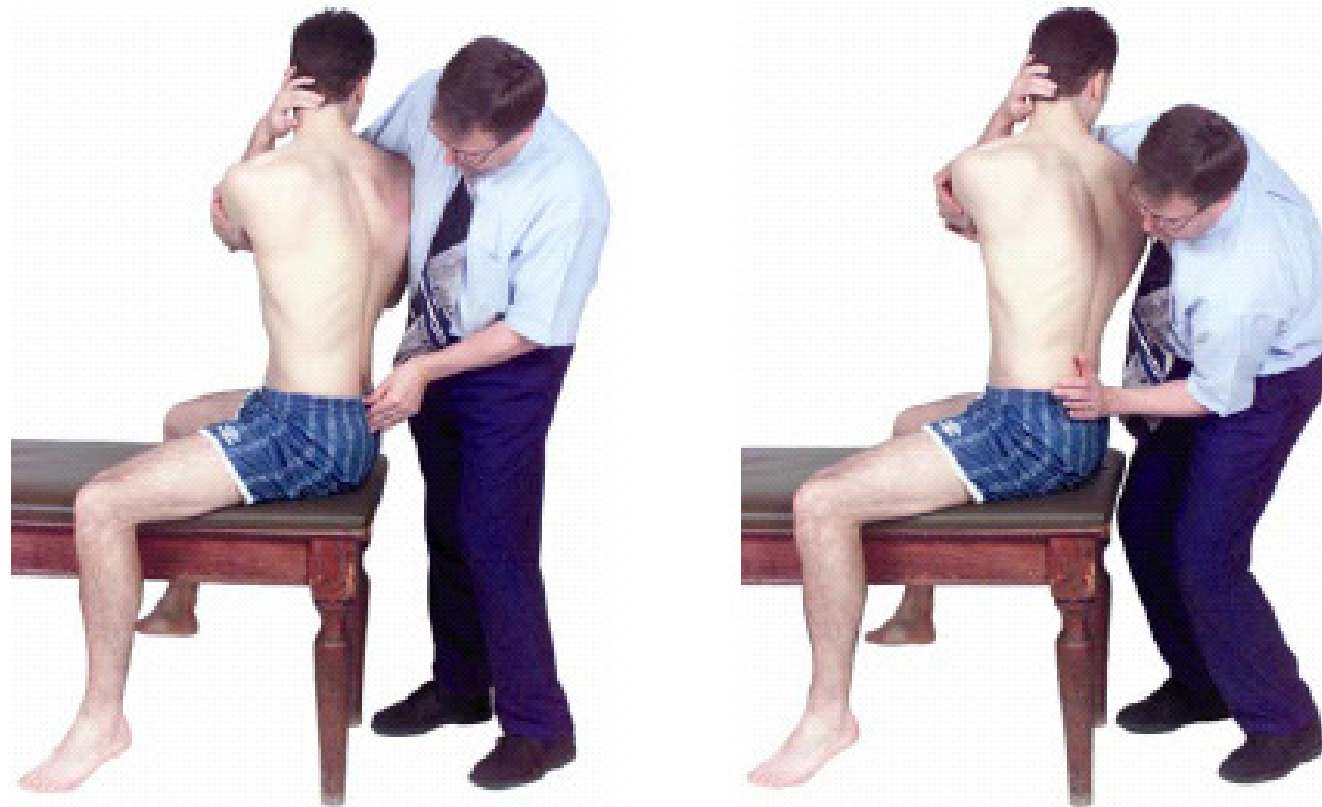

B. Seated--direct method—ME (isometric) and/or HVLA (4523.11B)

Diagnosis: Sacral Margin Posterior

1. Patient sits straddling the table near the end and the physician stands behind and to the side opposite the posterior margin
2. Patient places the hand on the side of the dysfunction behind his/her neck and grasps his/her elbow with the opposite hand
3. Physician reaches across the patient's chest and grasps the patient's arm on the opposite side. The physician's other hand monitors the posterior margin
4. Patient is instructed, "Sit up straight" and the physician rotates the patient's body away from the posterior margin to the restrictive barrier





5. Patient is instructed, "Without bending to the side, try to turn your body away from me"
6. Physician has the patient maintain the force long enough to sense that the patient's contractile force is localized at the lumbosacral junction (typically 3-5 seconds)
7. Patient is instructed to gently cease the directive force as the physician simultaneously ceases his/her counterforce
8. Physician waits for the tissues to relax completely (about 2 seconds) and then rotates the body and sacrum to the new restrictive barrier
9. Steps 5-8 are repeated until the best motion is obtained (average 3 times)
10. Recheck








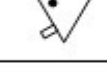
PELVIC SOMATIC DYSFUNCTION

POSITIONAL DIAGNOSIS	ASIS	PSIS	Pubic symphysis	Pubic tubercle
Anterior innominate	inferior	superior	-	-
Posterior innominate	superior	inferior	-	-
Superior innominate shear	superior	superior	-	-
Inferior innominate shear	inferior	inferior	-	-
Pubic compression	-	-	tender	symmetrical
Superior pubic shear	-	-	tender	superior
Inferior pubic shear			tender	inferior

SACRAL DIAGNOSIS

Diagnosis	Seated Flexion Test	Sacral Base/Sulci	ILA levelness	L5 Rot	Spring Test	LS Flexion Asymmtry
Left on left	Right	Anterior right	Posterior left	Right	Negative	Decreased
Left on Right	Left	Anterior right	Posterior left	Right	Positive	Increased
Right on right	Left	Anterior left	Posterior Right	Left	Negative	Decreased
Right on Left	Right	Anterior Left	Posterior Right	Left	Positive	Increased
Left Unilat Flex	Left	Anterior Left	Posterior Left	-	Negative	Decreased
Left Unilat Ext	Left	Anterior Right	Posterior Right	-	Positive	Increased
Right Unilat Flex	Right	Anterior Right	Posterior right	-	Negative	Decreased
Right Unilat Ext	Right	Anterior Right	Posterior left	-	Positive	Increased
Ant Margin - R	Right	Anterior Right	Anterior Right	Left	Negative	Decreased
Ant Margin – L	Left	Anterior Left	Anterior Left	Right	Negative	Decreased
Post Margin – R	Right	Shallow R	Posterior Right	Right	Positive	Increased
Post Margin – L	Left	Shallow L	Posterior Left	Left	Positive	Increased
Bilateral Flexion	N/A	Deep Bilateral	Shallow Bilateral	-	Negative	N/A
Bilateral Extnsn	N/A	Shallow Bilateral	Deep Bilateral	-	Positive	N/A

SACRUM SOMATIC DYSFUNCTION DIAGNOSIS

DIAGNOSIS	Seated flexion test ¹	Sacral base levelness ²	ILA levelness	L5 rotation ³	Sacral motion testing ⁴
Left on left torsion ⁵ 	right	anterior right	posterior left	right	extension restriction
Left on right torsion ⁵ 	left	anterior right	posterior left	right	flexion restriction
Right on right torsion ⁵ 	left	anterior left	posterior right	left	extension restriction
Right on left torsion ⁵ 	right	anterior left	posterior right	left	flexion restriction
Left unilateral flexion ⁶ 	left	anterior left	posterior left	-	extension restriction
Left unilateral extension ⁶ 	left	anterior right	posterior right	-	flexion restriction
Right unilateral flexion ⁶ 	right	anterior right	posterior right	-	extension restriction
Right unilateral extension ⁶ 	right	anterior left	posterior left	-	flexion restriction

¹ With a sacral torsion the seated flexion test is positive on the opposite side of the involved oblique axis.

² With a sacral torsion the sacrum is rotated to the opposite side of the anterior sacral base.

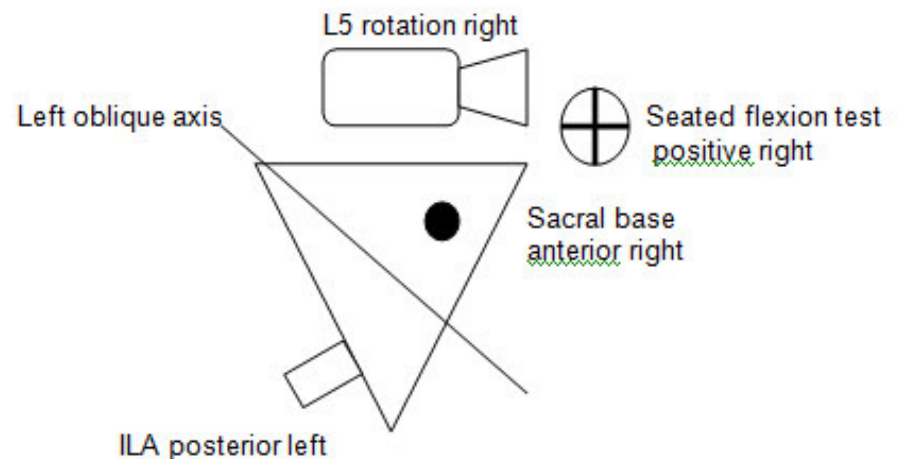
³ With a sacral torsion L5 is rotated to the opposite side of sacral rotation. If L5 is rotated to the same side as the sacrum the dysfunction is termed a sacral rotation.

⁴ Motion testing can be done with the lumbosacral spring test, backward bending test (lumbosacral flexion test), respiratory motion testing, or axis motion testing.

⁵ Torsions are named for the direction on the axis: Left on left torsion = rotation left on a left oblique axis.

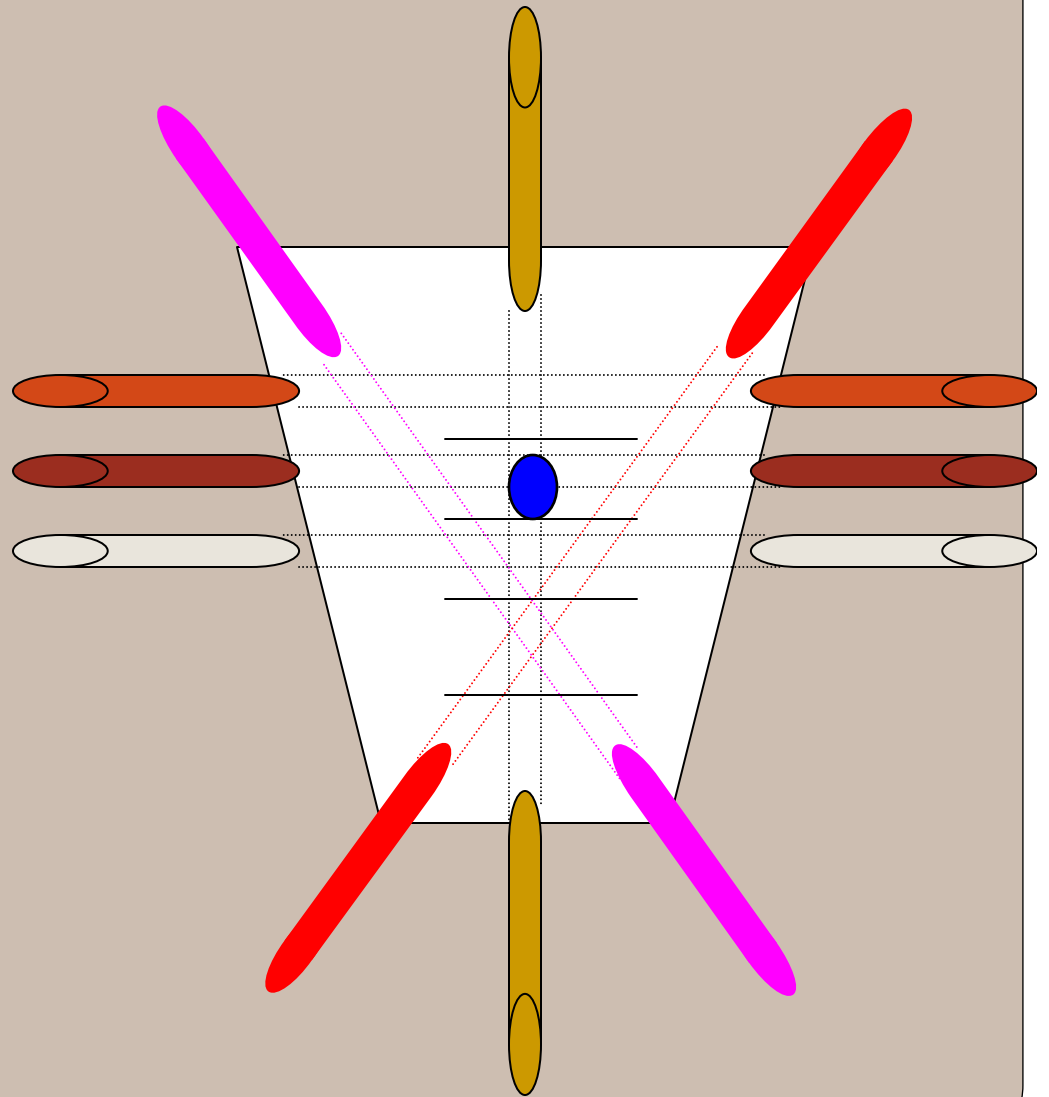
⁶ Also known as sacral shear.

KEY TO FIGURE: Findings for a left on left sacral torsion



Sacral Axes

- Multiple axes of motion:
 - Transverse (3)
 - Superior S1
 - Middle S2
 - Inferior S3
 - Vertical (sagittal)
 - A/P
 - Oblique (2)
 - Left
 - Right

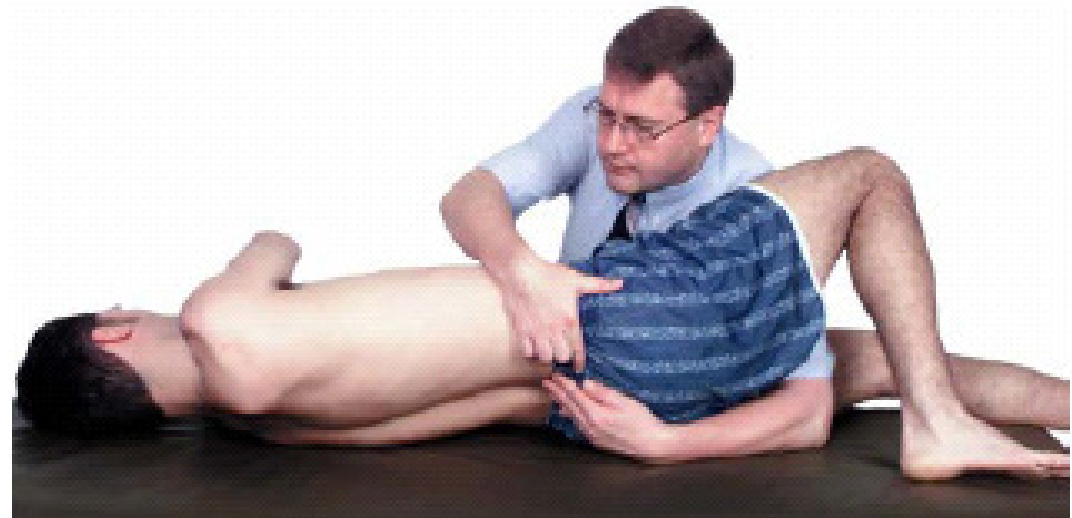



C. Supine--indirect method—respiratory force (4521.11C)

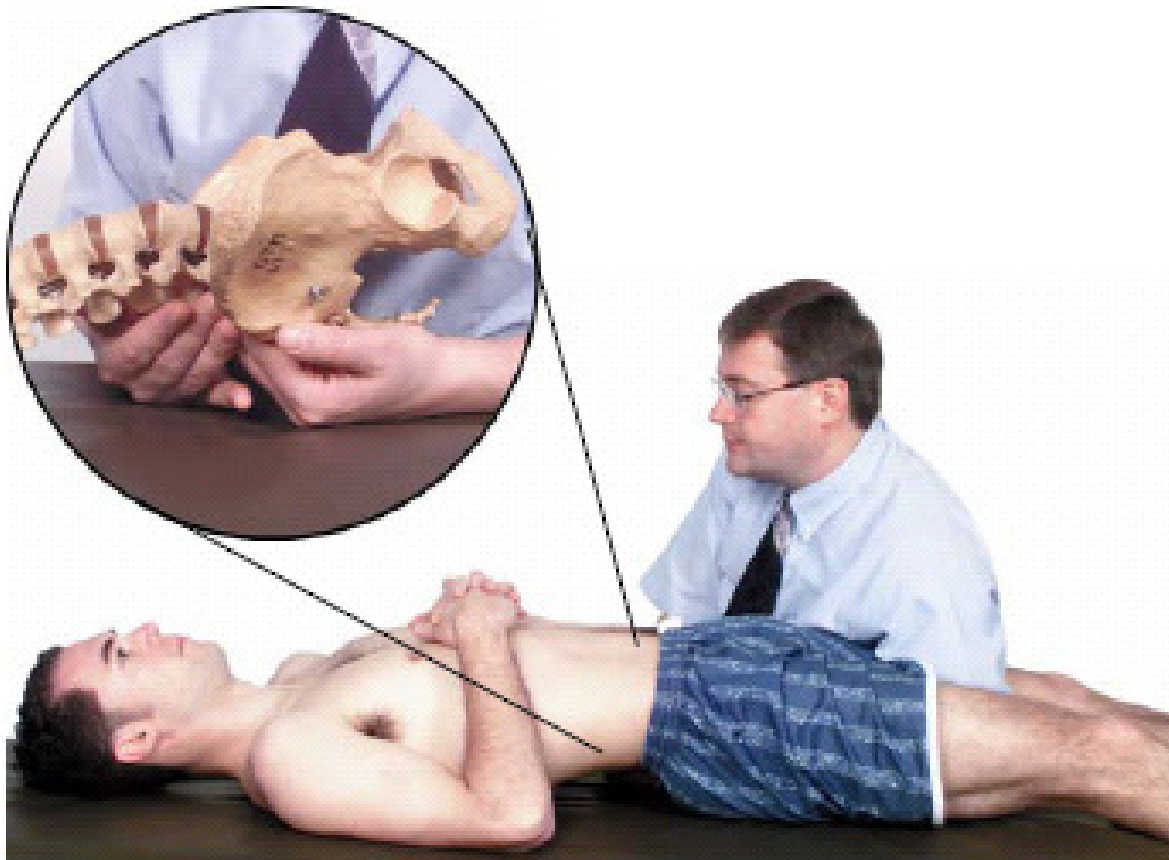
Diagnosis: Bilateral Sacral Flexion

1. Patient is supine and the physician stands at the side of the patient
2. Physician has the patient flex his/her knees and raise the pelvis off the table. The physician places his/her hand between the patient's thighs and under the sacrum. The patient is then asked to let the pelvis come back to the table and the patient's legs are extended. The physician's caudad hand is now cupping the sacrum with the fingers on the base and the palm on the apex
3. Physician then sits on a stool at the side of the table
4. Physician lifts the sacral bases anterior to the point of balanced ligamentous tension





Supine, indirect, respiratory cooperation, for bilateral flexion - 4521.11C



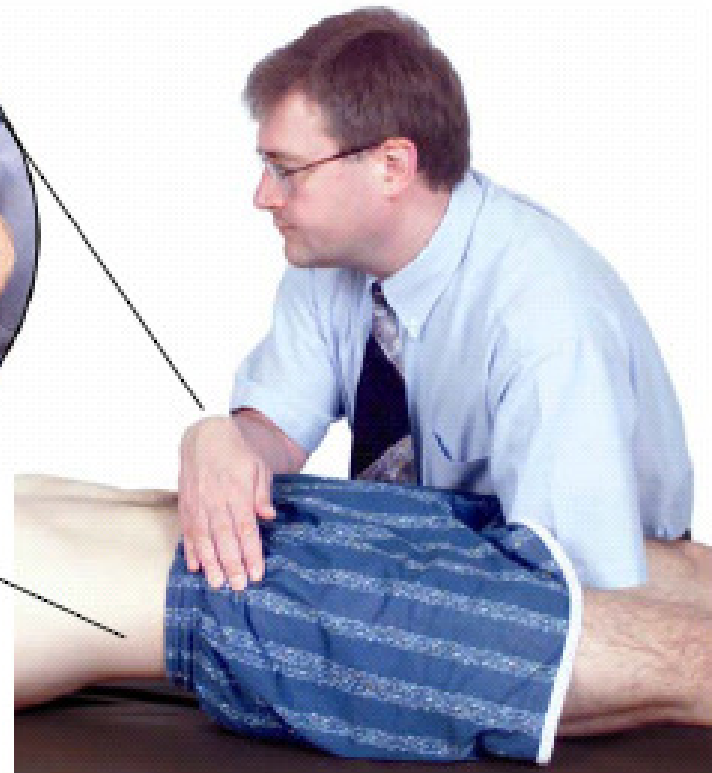
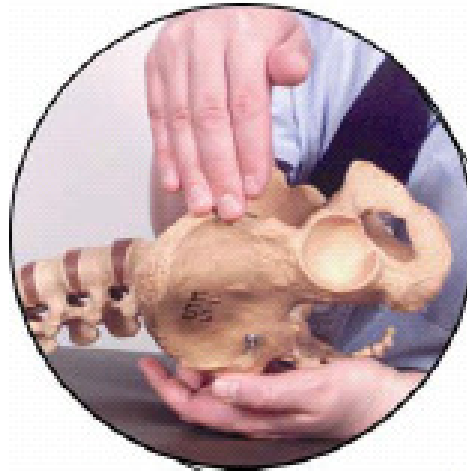5. Patient's respiratory phases are tested and he/she is instructed to hold the breath as long as possible in the phase that provides the best ligamentous balance
6. Step 5 is repeated until the best motion is obtained (average is 3 times)
7. Recheck.



C. Supine--indirect method—respiratory force (4522.11C)

Diagnosis: Bilateral Sacral Extension

1. Patient is supine and the physician stands at the side of the table
2. Physician has the patient flex his/her knees and raise the pelvis off the table. The physician places his/her hand between the patient's thighs and under the sacrum. The patient is then asked to let the pelvis come back to the table and the patient's legs are extended. The physician's caudad hand is now cupping the sacrum with the fingers on the base and the palm on the apex
3. Physician then sits on a stool at the side of the table
4. Physician lifts the sacral apex anterior to the point of ligamentous balance
5. Patient is instructed, "Take a very deep breath and hold it as long as possible." The physician makes minor adjustments to maintain ligamentous balance
6. Step 5 is repeated until the best motion is obtained (average is 3 times)
7. Recheck.



Sacral Base Anterior

(several terms describing the same motion)

- Sagittal Plane-Middle Transverse Axis
- Bilateral Sacral Flexion
 - Kimberly manual 2006, p. 193 (4521.11A-E)
 - (different than the sacral “flexion & extension” in the Magoun-type cranial field model)
- Nutation
 - From the Latin “nutare”- to nod
 - Nutated Sacrum
- Anterior Nutation

Sacral Base Anterior

(Bilateral Sacral Flexion)

- Inferolateral angles level
- Sulci deep bilaterally
- Sacral base anterior bilaterally
- Sacrotuberous ligaments tight bilaterally
- Base anterior springing present
- Apex anterior springing restricted
- Look for “discontinuity” at the lumbo-sacral junction

Sacral Base Anterior:

Base bilat. anterior on the middle transverse axis

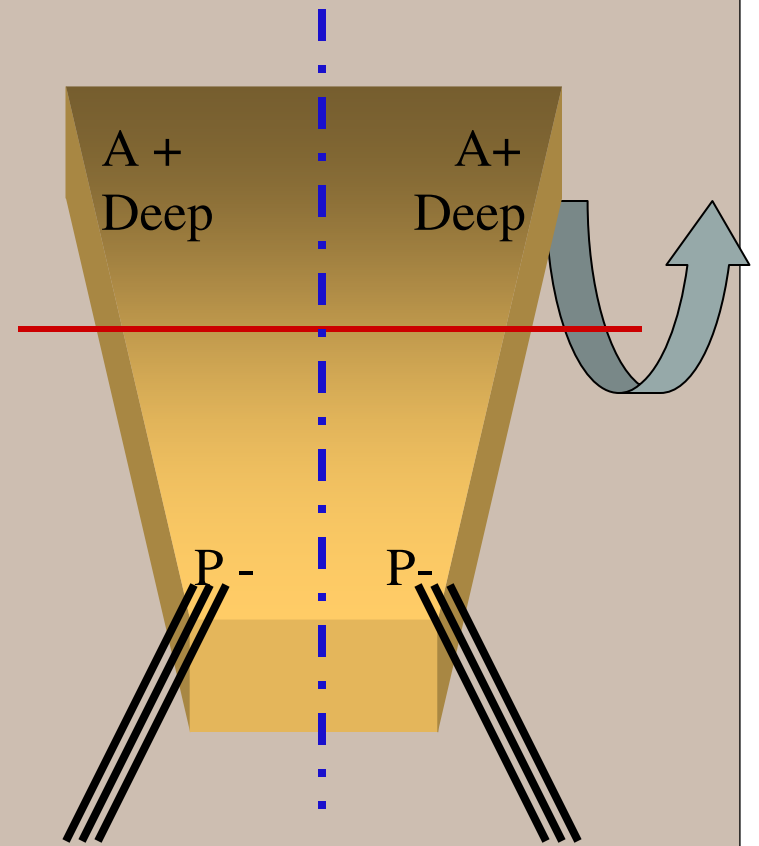
Name: Sacral Base Anterior,
Or bilat. Sacral Flexion, Or Nutation

Landmarks:

Sacral Base: Bilat. Anterior
Sacral Sulcus: Bilat. Deep
ILA: Bilat. Posterior
STL: Bilat. Tight

Motion:

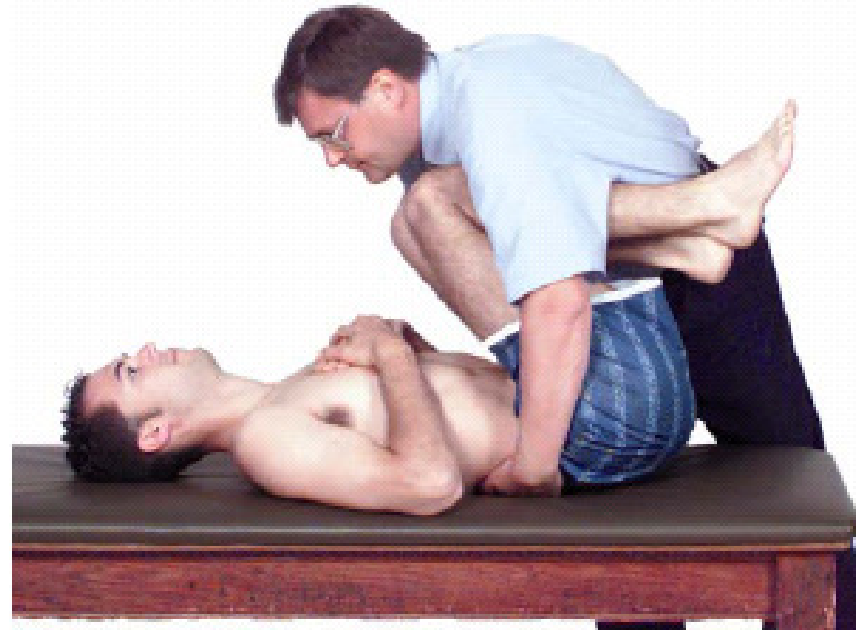
Sacral Base: Bilat. +
ILA: Bilat. -



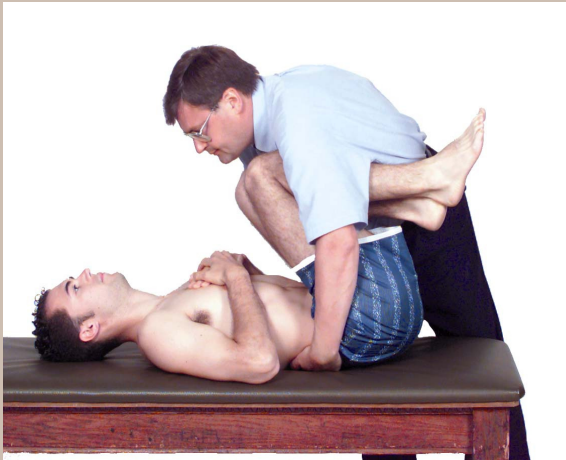D. Supine--direct method—ME (isometric) (4521.11D)

Diagnosis: Bilateral Sacral Flexion

1. Patient is supine with both lower extremities flexed with the knees over the abdomen. The physician stands at the side of the table with the patient's knees and legs resting on his/her chest
2. Physician reaches around each side of the patient to contact the paraspinal tissues lateral to L5
3. Physician increases flexion until the forces are localized at the lumbosacral junction
4. Patient is instructed, "Gently push your knees against me."
5. Physician has the patient maintain the force long enough to sense that the patient's contractile force is localized at the lumbosacral junction (typically 3-5 seconds)
6. Patient is instructed to gently cease the directive force and the physician simultaneously ceases his/her counterforce
7. Physician waits for the tissues to relax completely (about 2 seconds) and then flexes the lumbosacral joint to the new restrictive barrier
8. Steps 4-7 are repeated until the best motion is obtained (average is 3 times)
9. Recheck



Muscle Energy Bilateral Sacral Flexion



Physician contacts paraspinal muscles lateral to L5

Flex patient until motion is localized at lumbosacral junction

Have patient attempt to gently straighten legs

Resist

Rest

Re-engage flexion and repeat

Sacral Base Posterior

- Sagittal Plane-Middle Transverse Axis
- Bilateral Sacral Extension
 - Kimberly manual 2006, p. 197 (4522.11A-C)
 - (different than sacral “flexion & extension” in the Magoun-type cranial field model)
- Counter Nutation
- Posterior Nutation

Sacral Base Posterior

(Bilateral Sacral *Extension*)

- Inferolateral angles level
- Sulci *shallow* bilaterally
- Sacral base *posterior* bilaterally
- Sacrotuberous ligaments “*relaxed*” bilaterally
- Apex anterior springing present
- Base anterior springing restricted

Sacral Base Posterior

Base bilat. posterior on the middle transverse axis

Name: Sacral Base Posterior,

Bilat. sacral extension ,or Counternutation

Landmarks:

Sacral Base: Bilat. Posterior

Sacral Sulcus: Bilat. Shallow

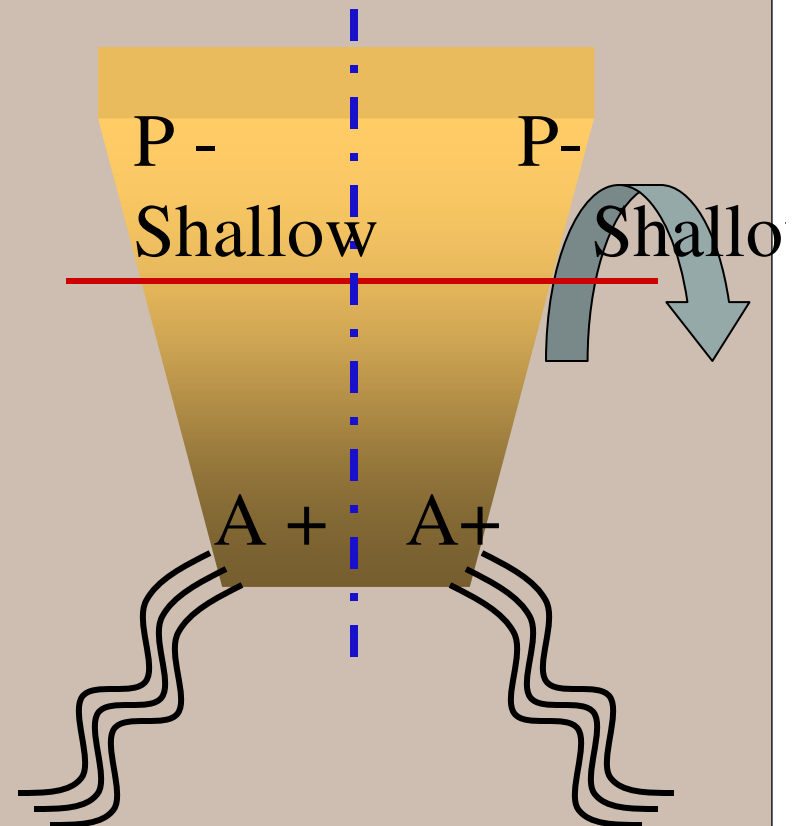
ILA: Bilat. Anterior

STL: Bilat. Loose

Motion:

Sacral Base: Bilat. -

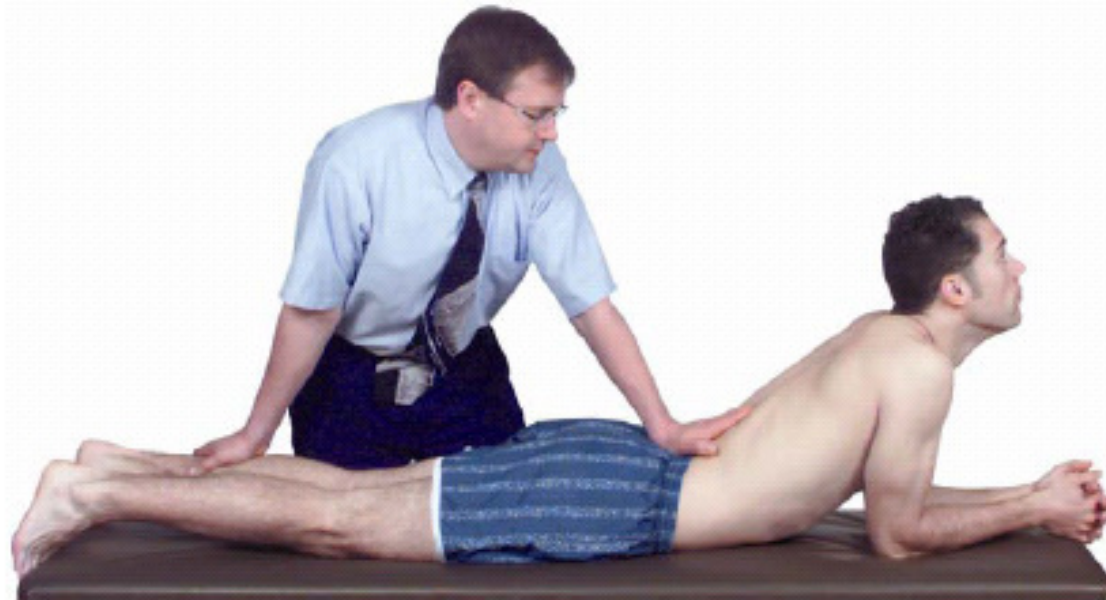ILA: Bilat. +



B. Prone--direct method—patient cooperation, respiratory force (4522.11B)

Diagnosis: Bilateral Sacral Extension

1. Patient is prone, supporting the upper trunk on his/her elbows and the physician stands at the side of the table
2. Physician places the heel of his/her cephalad hand over the patient's sacral base and places his/her caudad hand on the patient's ankle or leg to provide counterforce



3. The sacral base is carried anteriorly to the restrictive barrier
4. Patient is instructed, "Take a very deep breath" and the physician resists the posterior motion of the sacral base
5. Physician then instructs the patient, "Bend backwards as you let your breath out completely" while the physician follows the sacral base forward
6. Steps 4-5 are repeated until the best motion is obtained (average is 3 times)
7. Recheck

SACRAL MECHANICS

- Physiologic diagnoses of the sacrum occur in **neutral** and **non-neutral** mechanics:

Neutral Mechanics a.k.a.

or

- Left rotation on a Left Oblique Axis
- Forward Torsion
- Sacral Nutation

or

(all three are equivalent terms!!)

- **In neutral mechanics, the sacrum rotates in the same direction as the oblique axis (left rotation on a left oblique axis)**

Non-neutral Mechanics a.k.a.

or
or

- Right rotation on a Left Oblique Axis
- Backward Torsion
- Sacral Counter-Nutation

(all three are equivalent terms!!)

- **In non-neutral mechanics, the sacrum rotates in the opposite direction of the oblique axis (right rotation on a left oblique axis)**

FRYETTE'S LAWS

- **Law I:** When the spine is in neutral, **sidebending to one side** will be accompanied by horizontal **rotation to the opposite side**. In **type I somatic dysfunction** this law can be seen when more than one **vertebrae** are out of alignment and cannot be returned to neutral by flexion or extension. The involved group of vertebrae demonstrates a coupled relationship between side bending and rotation. When the spine is neutral, side bending forces are applied to a group of typical vertebrae and the entire group will rotate toward the opposite side: the side of produced convexity [2] Extreme type I dysfunction is similar to **scoliosis**.
- **Law II:** When the spine is flexed or extended (non-neutral), sidebending to one side will be accompanied by rotation to the same side. In **type II somatic dysfunction** of the spine, this law can be seen when only one vertebrae is out of place and becomes much worse on flexion or extension. There will be **rotation and sidebending in the same direction** when this dysfunction is present[3].
- **Law III:** When motion is introduced in one plane it will modify (reduce) motion in the other two planes.[4] Type III sums up the other two laws by stating dysfunction in one plane will negatively affect all other planes of motion